Prostate cancer imaging

Imaging in the Diagnosis and Management of Prostate Cancer

Peter L. Choyke MD
Molecular Imaging Program, National Cancer Institute
National Institutes of Health, Bethesda, MD

MIP
MOLECULAR IMAGING PROGRAM

NATIONAL CANCER INSTITUTE

Disclosures

- Inventor of US-Government owned patents:
  - A method of MRI-TRUS Fusion biopsy
  - A method of computer aided diagnosis (CAD) of prostate cancer
  - Another method of CAD for prostate cancer
  - A method of photoimmunotherapy
- CRADAs with GE, Philips, Philips-In vivo, Rakuten Medical-Aspyrian
- No financial disclosures to report

Prostate cancer

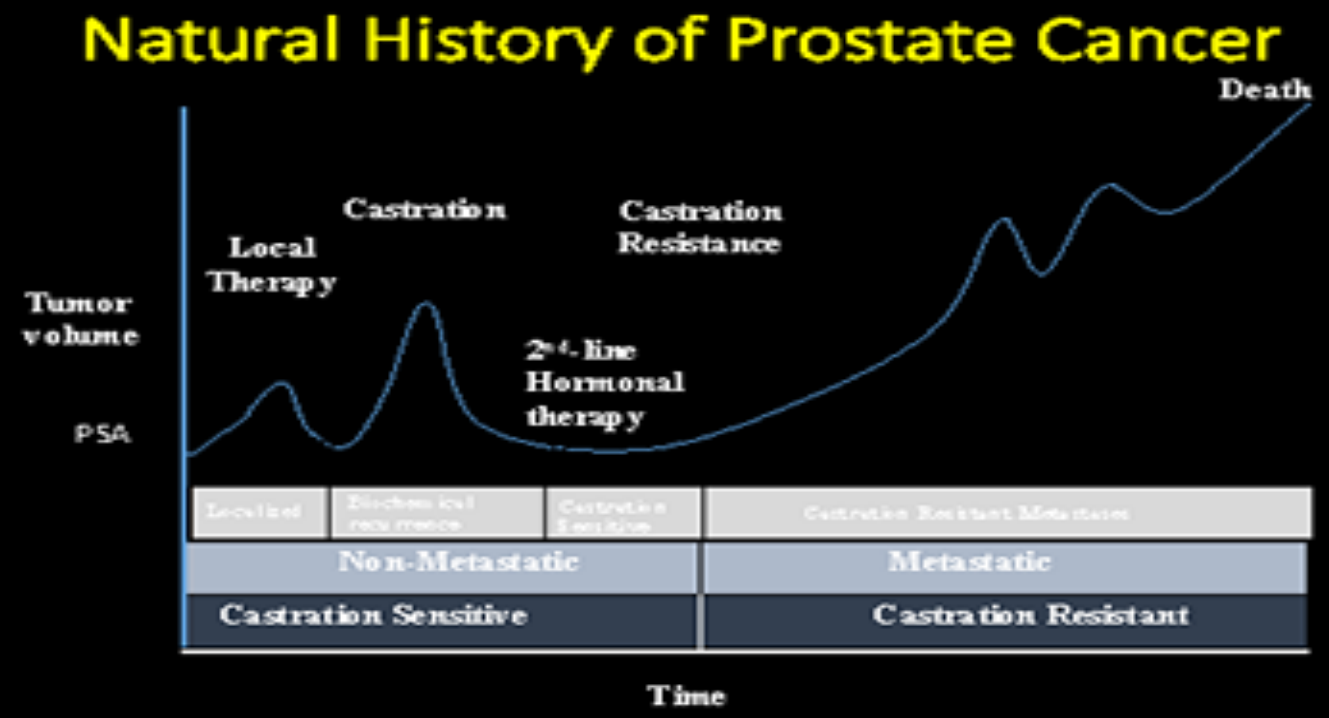

Prostate biopsy

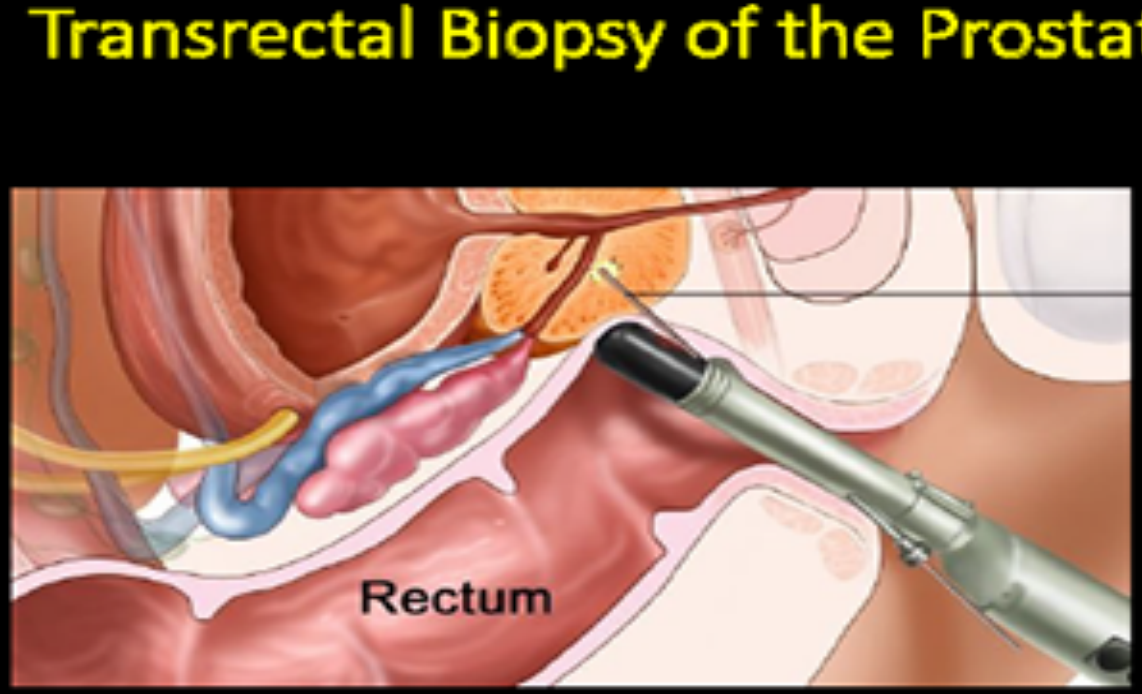

Ultrasound guided biopsy

Problems with the Transrectal Ultrasound Guided Biopsy

Underdiagnosis



Poor Sampling

Overdiagnosis

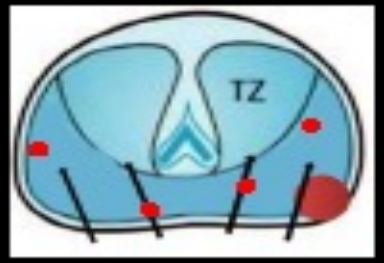

Spectrum of diseases

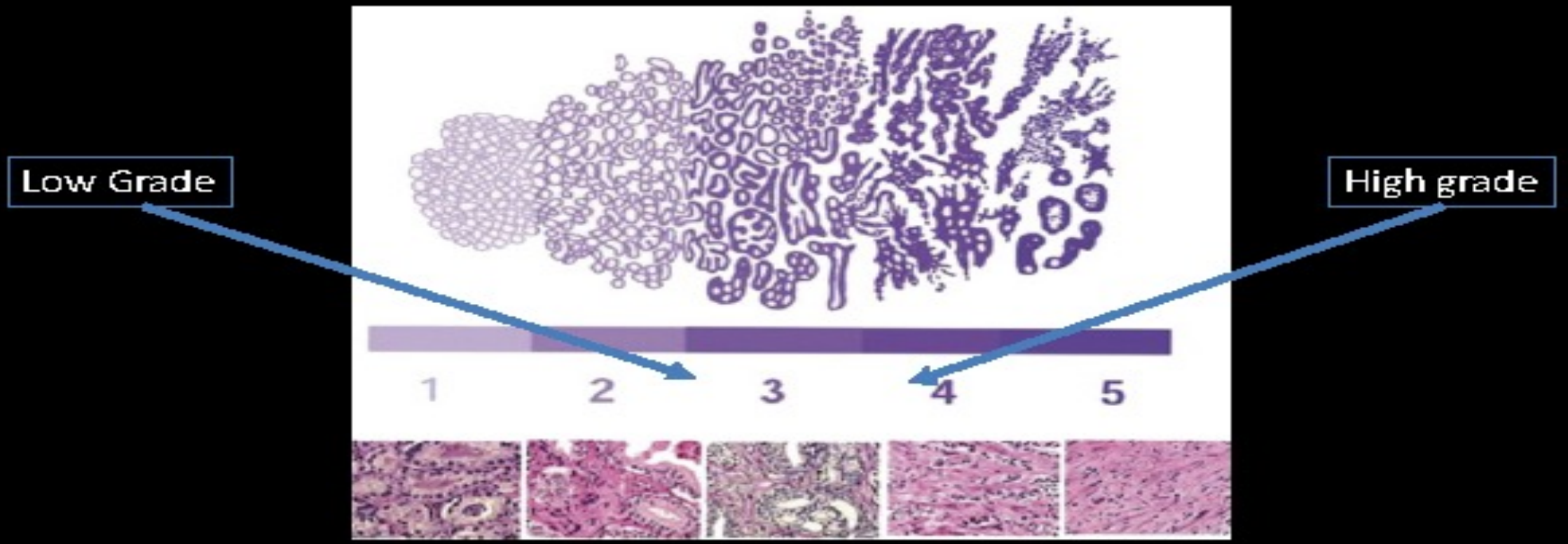

Prostrate cancer treatment

For men with low grade cancers: Active Surveillance
For men with intermediate-high grade: Radiation Therapy or Surgery

PSA tests are obtained to monitor for recurrence
~30% of men will show rising PSA indicating possible recurrence
Known as "biochemical recurrence"

Prostate Cancer can spread to nodes and bones: metastatic prostate cancer
Treated with androgen deprivation therapy (ADT): met Castrate sensitive PCA
When ADT fails: metastatic Castrate resistant PCA

Pca progression

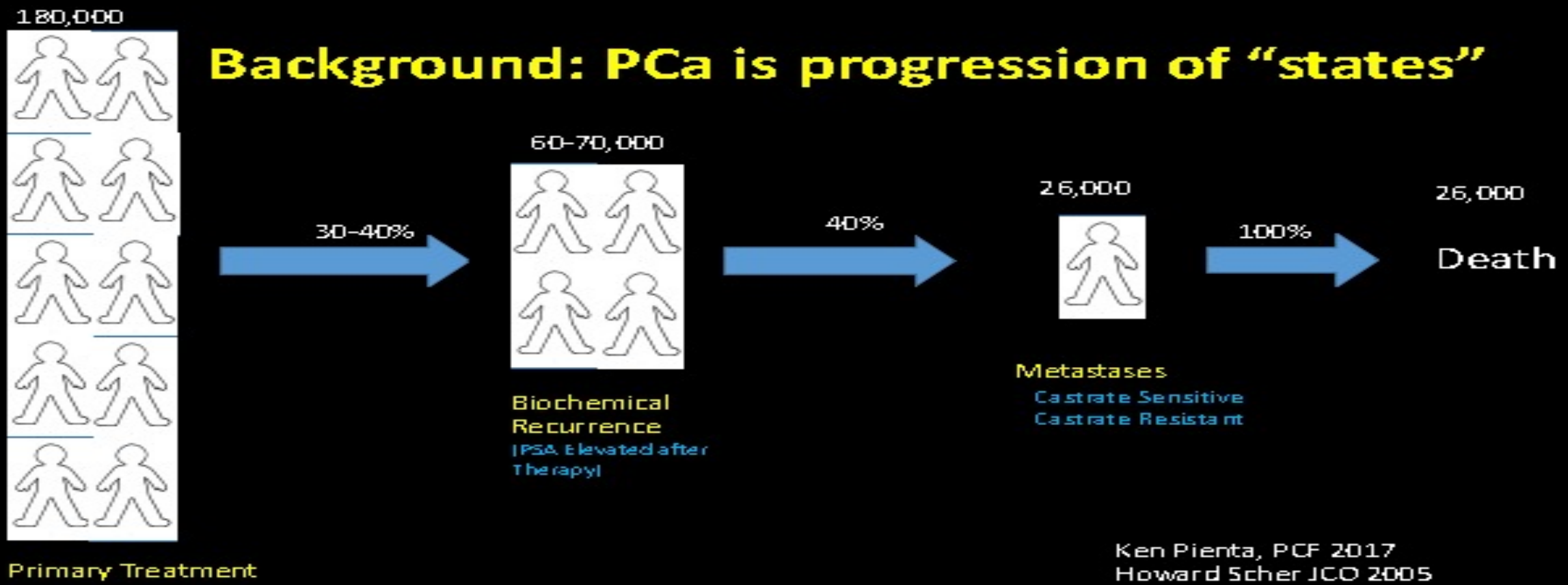

Ken Pienta, PCF 2017
Howard Scher JCO 2005

Diagnosis

Diagnosis

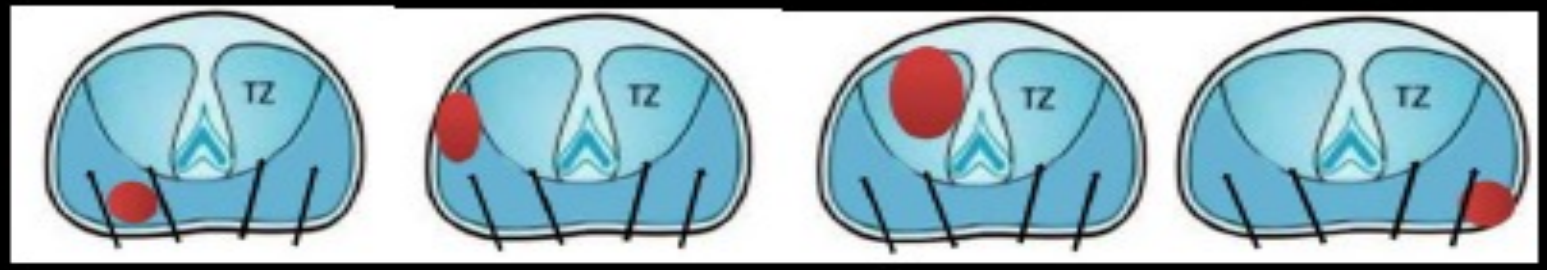

"Why is the prostate the only organ in the body that is biopsied blind?" Peter Pinto, MD circa 2003

Multi-parametric MRI

Multi-parametric Prostate MRI

Endorectal coil

16-channel
cardiac coil

T2 Weighted MRI
Diffusion Weighted MRI (DWI)
Dynamic Contrast Enhanced MRI (DCE)

Baris Turkbey, MD

MRI anatomy

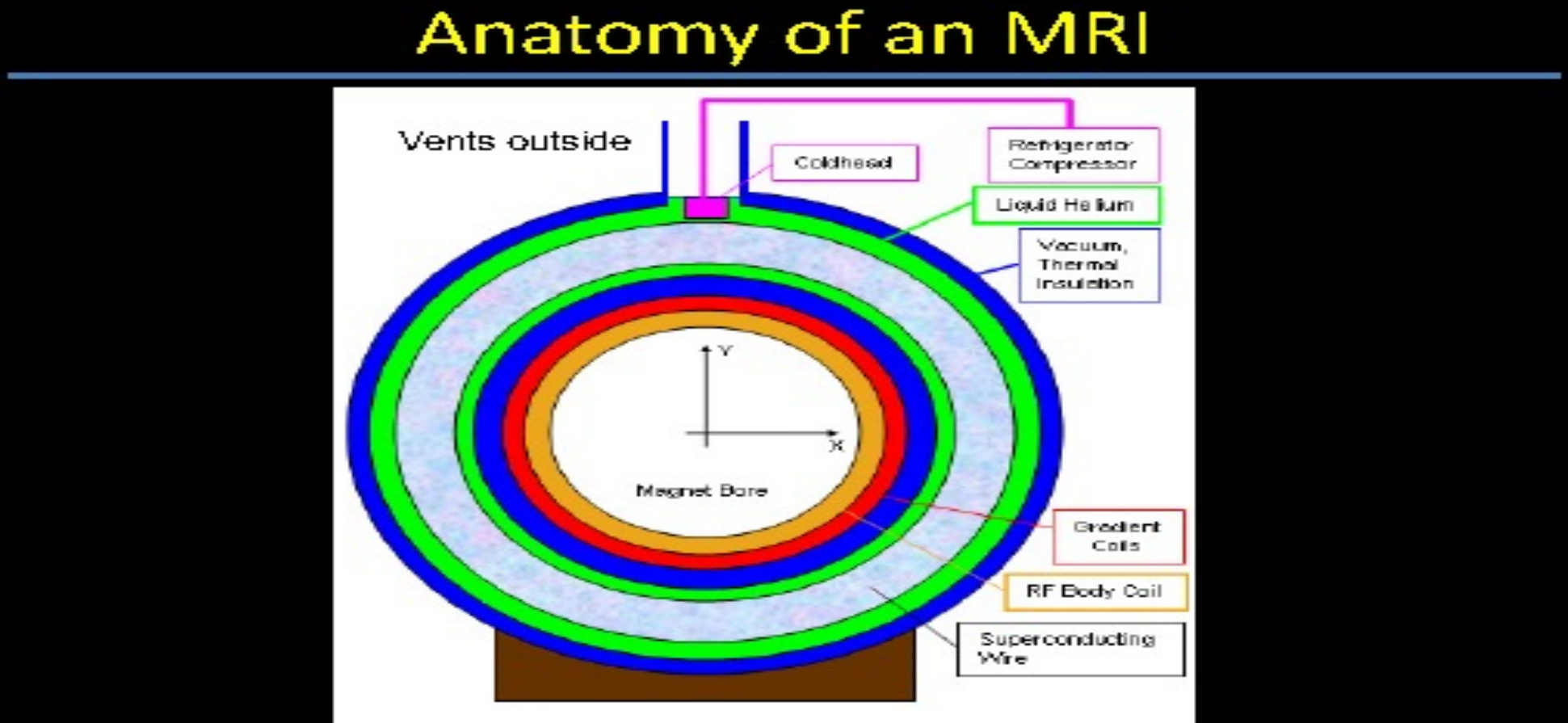
Anatomy of an MRI
Vents outside
Coldhead
Refrigerator Compressor
Liquid Helium
Vacuum, Thermal Insulation
Y
X
Magnet Bore
Gradient Coils
RF Body Coil
Superconducting Wire

MRI Imaging

1

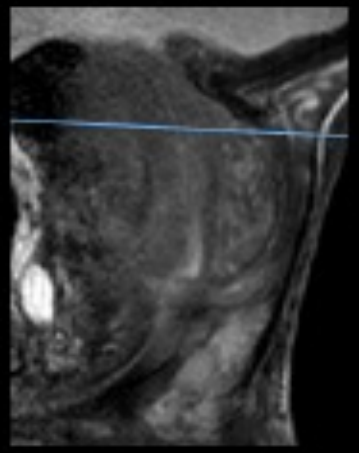

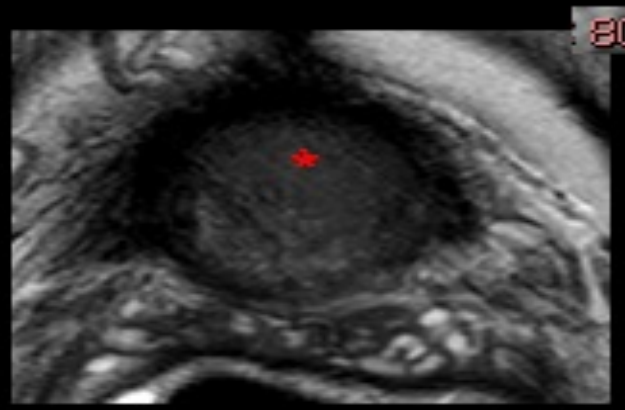

T2

64 y.o. with rising PSA after multiple negative biopsies

Midline base anterior central gland lesion

T2 +

DWI +

DCE +

Highly suspicious

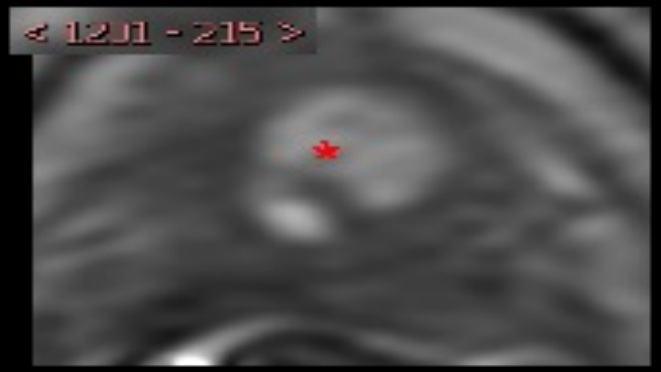

DCE

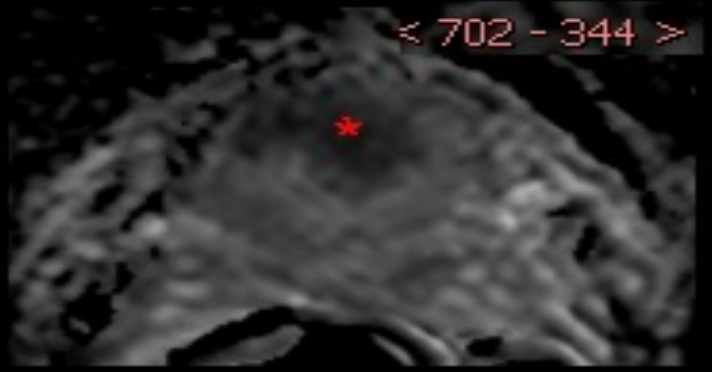

ADC map

Tumor detection

74-year-old man, PSA=7.33ng/dl, 2 prior negative TRUS guided biopsy

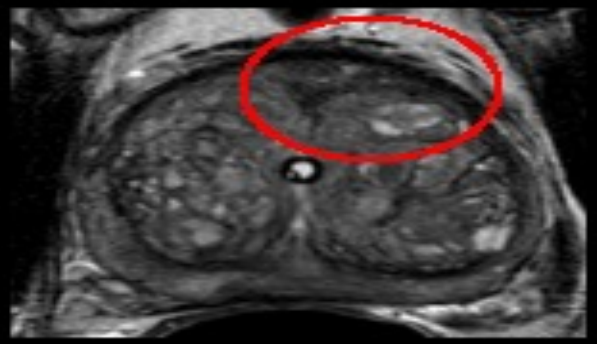

T2

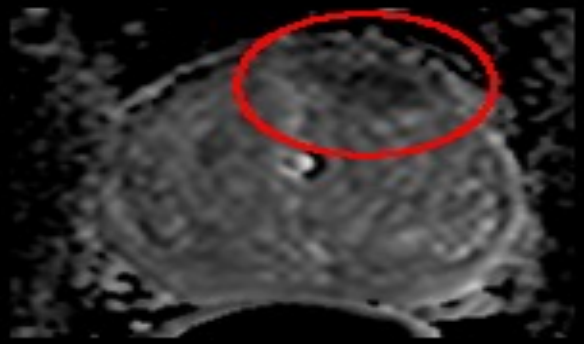

Diffusion-ADC

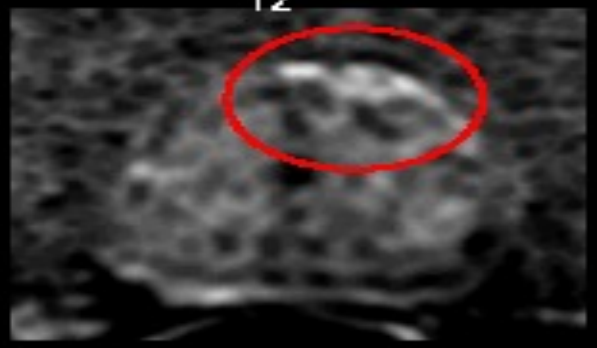

Diffusion-high b-value

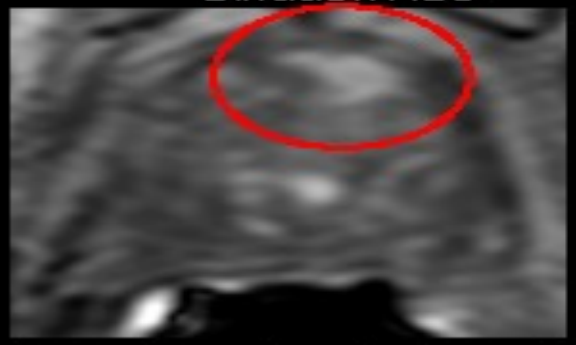

Dynamic contrast enhanced MRI

Left mid anterior TZ-1.8cm

Gleason 3+4 (60% core involvement)

Prostate tumor

72-year old man with a serum PSA=38.6ng/dl with 3 prior TRUS guided biopsies

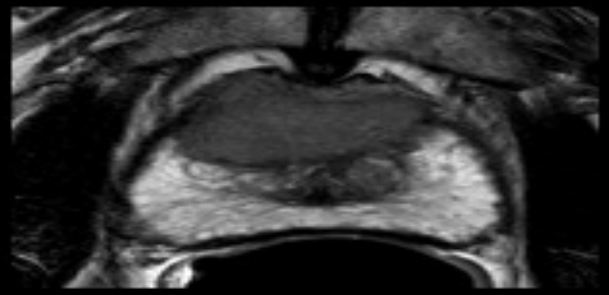

T2W MRI

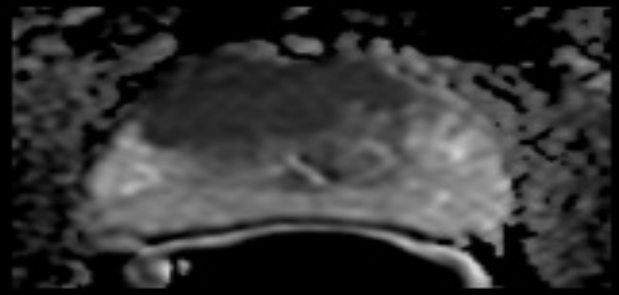

ADC map

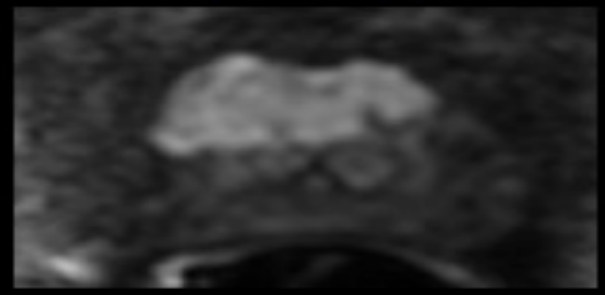

B=2000 DWI

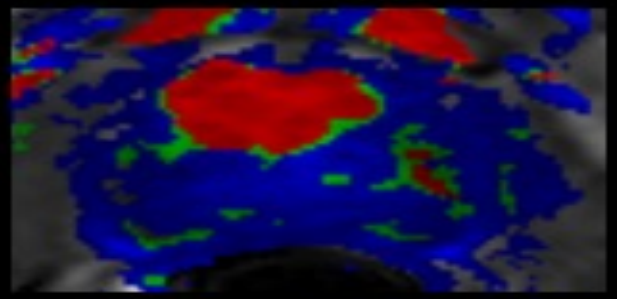

Color encoded contrast enhancement

Brad Wood, MD

Prostate fusion

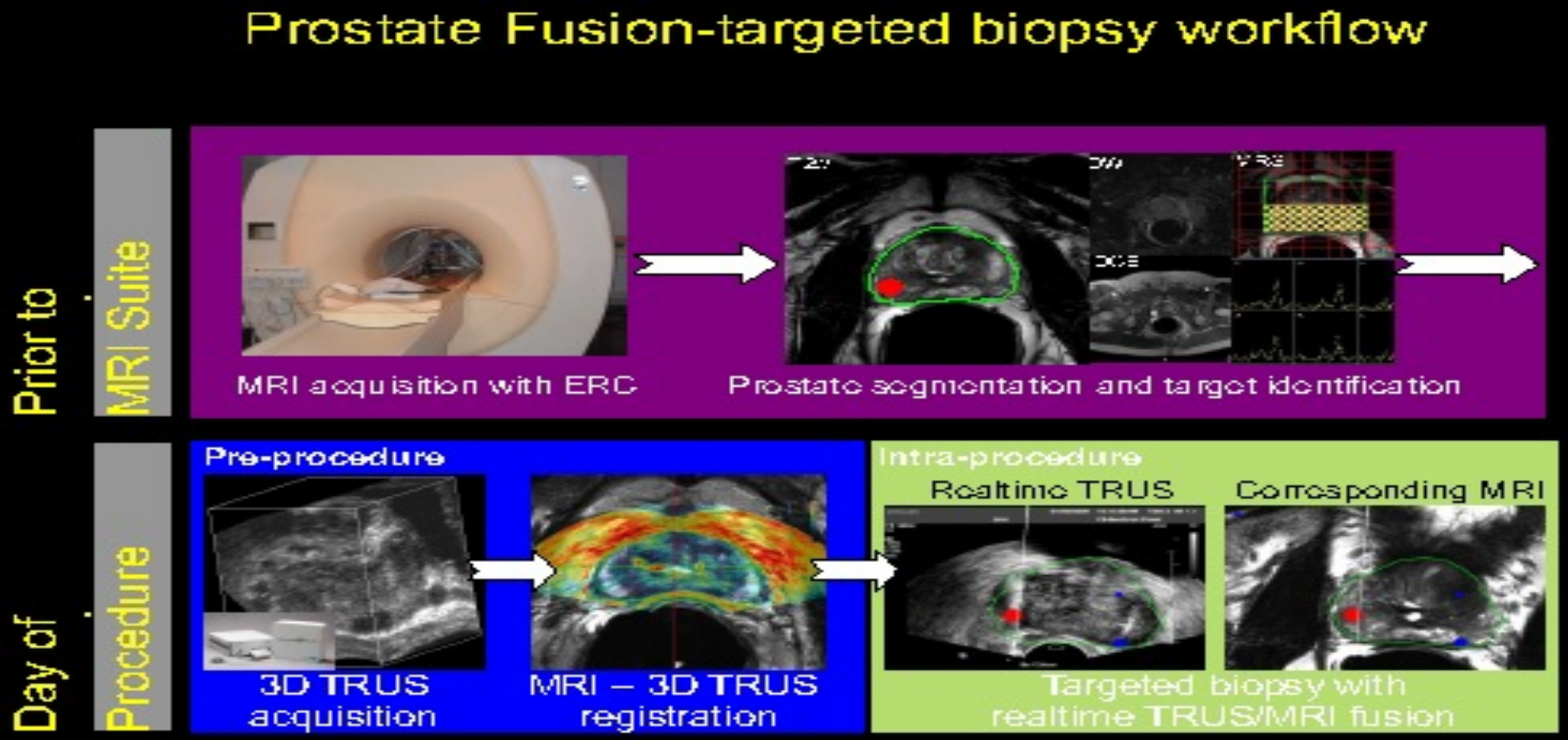

Prostate tumor Ultrasound fusion

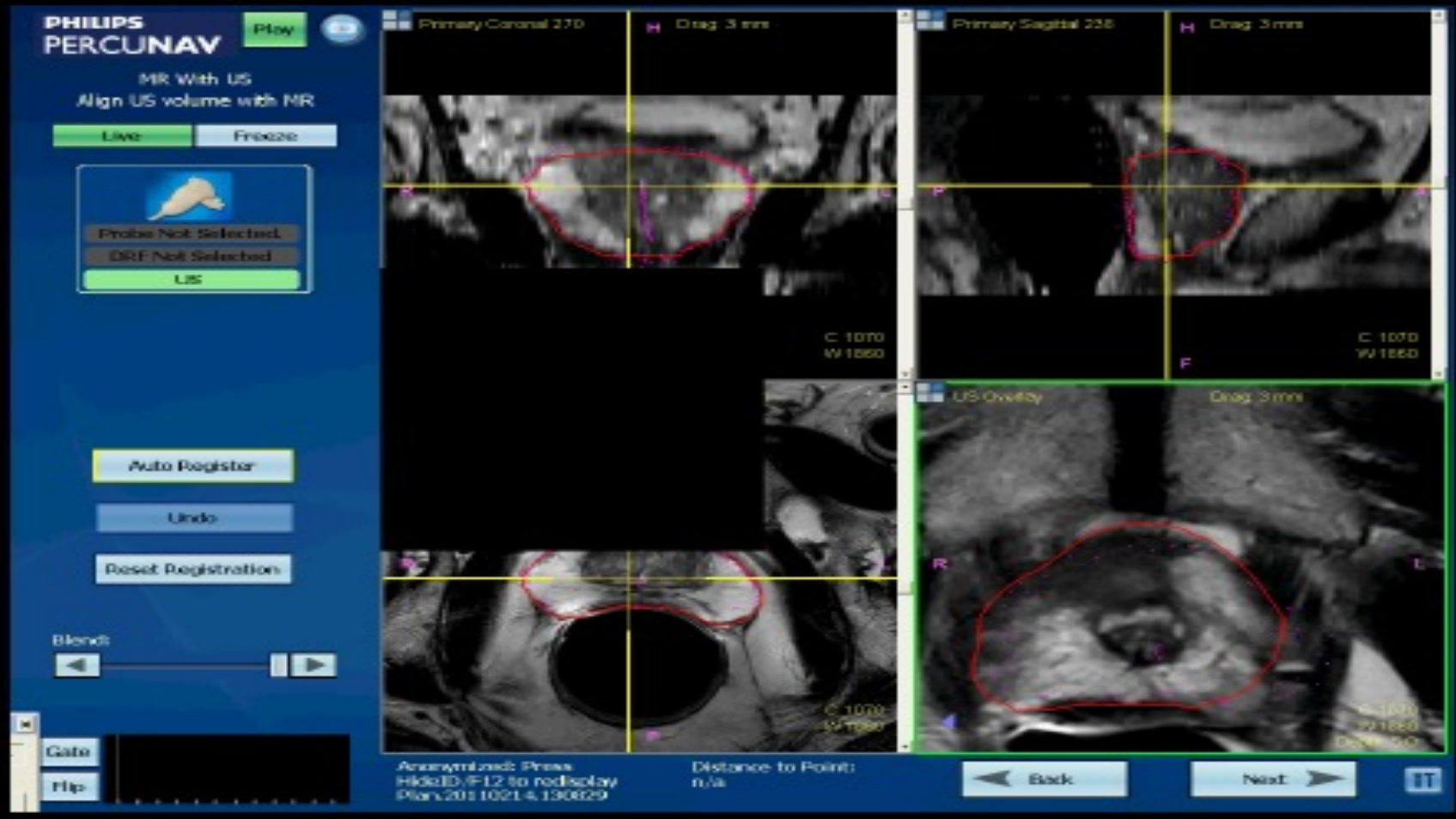

Ultrasound fusion

Original Investigation

Comparison of MR/Ultrasound Fusion–Guided Biopsy With Ultrasound-Guided Biopsy for the Diagnosis of Prostate Cancer

M. Minhaj Siddiqui, MD; Soroush Rais-Bahrami, MD; Baris Turkbey, MD; Arvin K. George, MD; Jason Rothwax, BS; Nabeel Shakir, BS; Chinonyerem Okoro, BS; Dima Raskolnikov, BS; Howard L. Parnes, MD; W. Marston Linehan, MD; Maria J. Merino, MD; Richard M. Simon, DSc; Peter L. Choyke, MD; Bradford J. Wood, MD; Peter A. Pinto, MD

- Key findings in over 1000 cases
  - 30% increase in the diagnosis of high-risk cancers using targeted biopsy
  - 17% decrease in the diagnosis of clinically-insignificant low risk cancers

Siddiqui M et al. JAMA 2015

JAMA. 2015;313(4):390-397. doi:10.1001/jama.2014.17942

PRECISION study

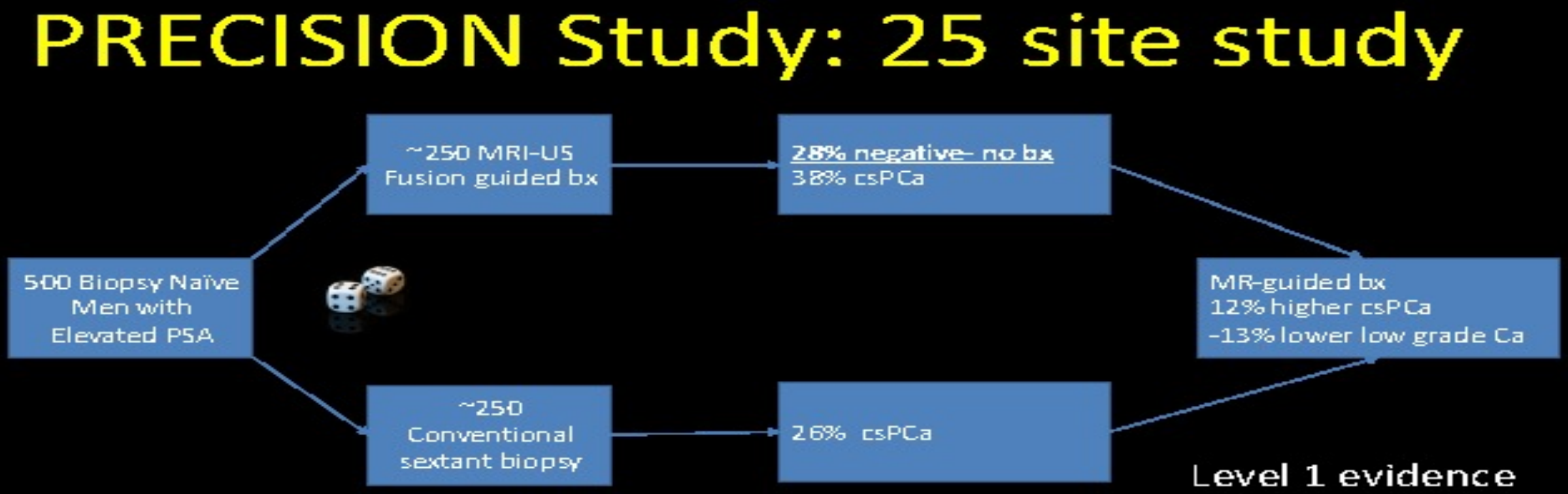

Kasivisvanathan et al NEJM 2018

Prostate imaging development

The Development of Prostate Imaging and Image Guided Biopsy 2000-2016

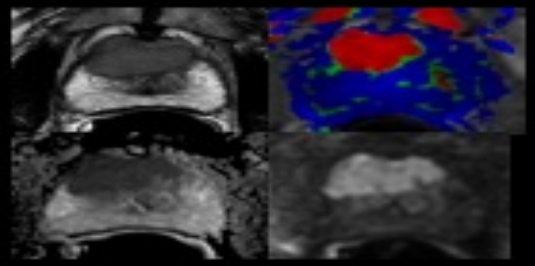

Multiparametric MRI 2000's

In gantry biopsy 2003-6

MRI-TRUS-GPS-2006

Clinical MR-TRUS Fusion 2008

Commercial MR-TRUS fusion Devices 2013

World wide- Image Guided Bx (IGB) 2018

TRUS fusion industry

MRI TRUS Fusion Industry since 2010

MR-TRUS Fusion Software (Manufacturer)	US Image Acquisition	Method of Registration	Tracking System	Manipulation	Sampling Route	Targeting
Artemis (Eigen)	Manual	Non-rigid	Mechanical Arm with encoders	Via Mechanical Arm	Transrectal	Prospective
BioJet (GeoScan)	Manual	Rigid	Stepper with digital encoders	Via Stepper	Transrectal or Transperineal	Prospective
BiopSee (MedCom)	Manual	Rigid	Stepper with digital encoders	Via Stepper	Transperineal	Prospective
RealTime Virtual Sonography (Hitachi)	Manual	Rigid	Electromagnetic	Freehand	Transrectal or Transperineal	Prospective
UroNav (InvivoPhilips)	Manual	Rigid	Electromagnetic	Freehand	Transrectal	Prospective
Urostation (Koelis)	Automatic	Non-rigid	3D Ultrasound	Freehand	Transrectal	Retrospective
Varisced (Varian Medical System)	Manual	Rigid	Stepper with digital encoders	Via Stepper	Transperineal	Prospective
Virtual Navigator (Esaote)	Manual	Rigid	Electromagnetic	Freehand	Transrectal	Prospective

NIH Patent: 2007

Valerio et al. Eur Radiology 2015

Laser ablation

Focused Laser Ablation-Local Therapy

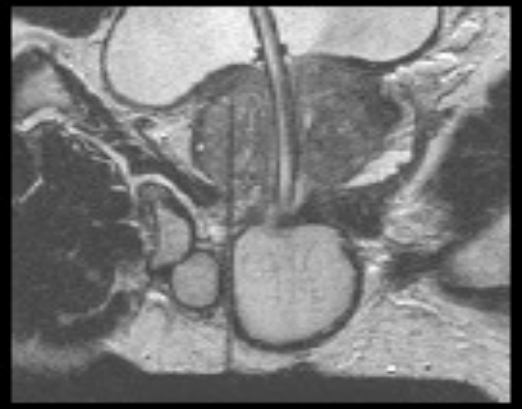

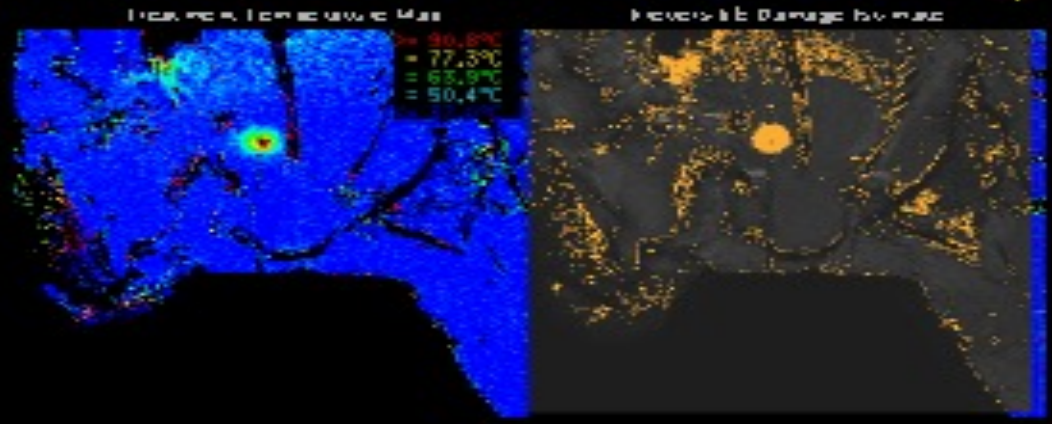

Test dose
3.75 W for 34 sec

Laser Doses
12 W for 32, 25 and 68 sec

Damage 18 mm by 17 mm

Temperature safety limits were set to protect the urethra, shutting down the laser power automatically.

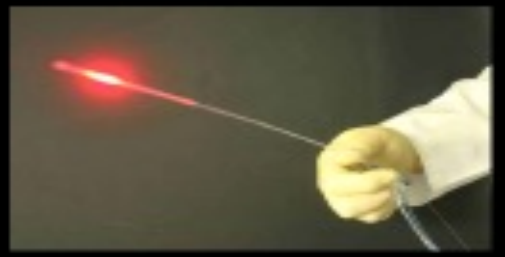

Baris Turkbey

Peter Pinto

Brad Wood

Cancer views

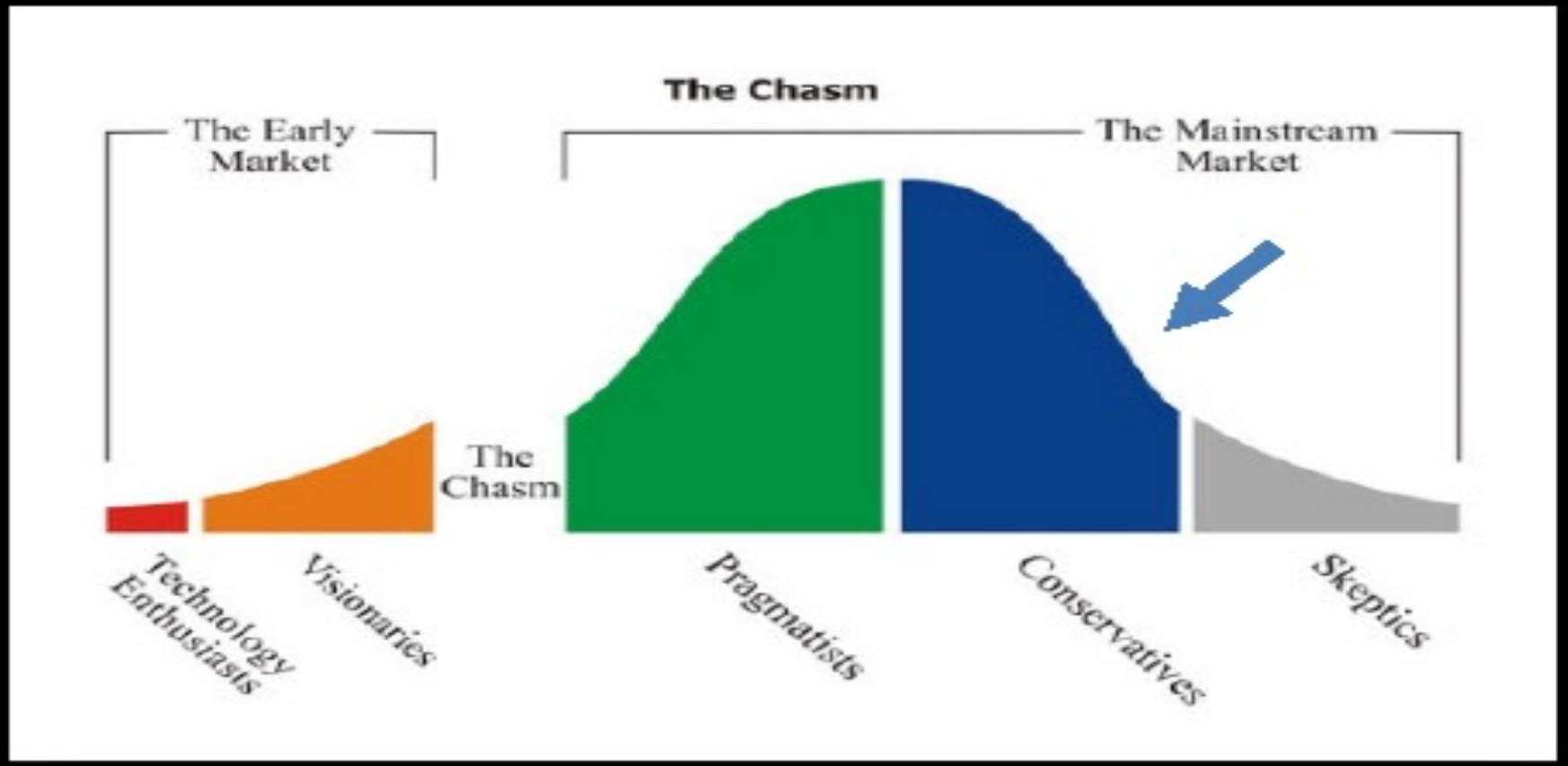

False negative rate

The MR negative lesion: False negative rate =5-20%

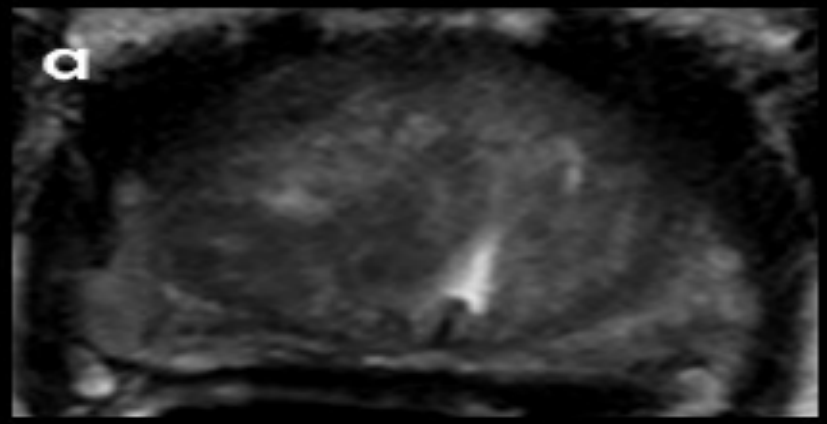

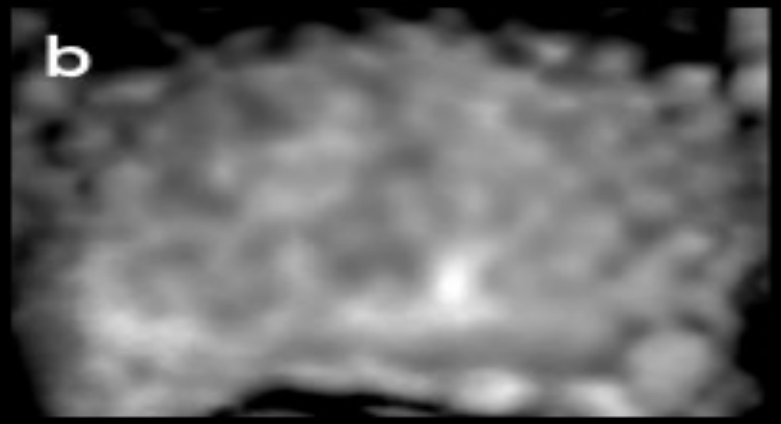

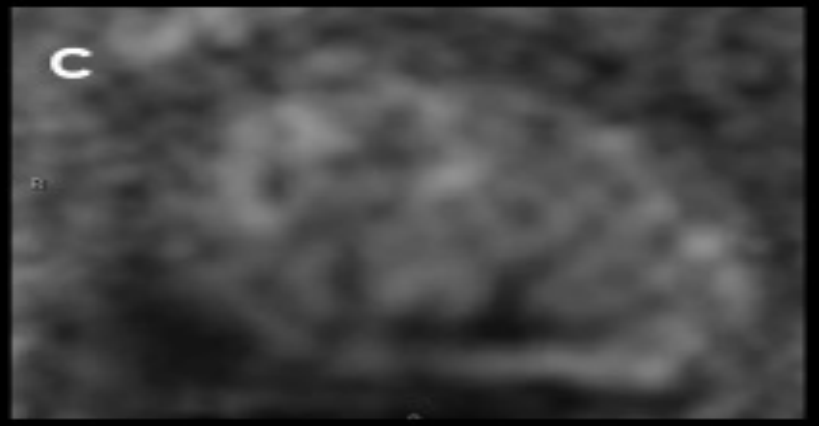

What are we missing?
Borofsky et al. Radiology, 2018

Lack of standards

Lack of Standards: Prostate Imaging, Reporting and Data System Version 2 (PI-RADSv2)

- Each lesion is scored PI-RADS 1 to 5
  - Rules:
  - Score each T2W, DWI, DCE separately
  - In PZ DWI predominates
  - In TZ T2 predominates
  - DCE MRI helps in equivocal cases
  - What does a PIRADS score mean:
    - Likelihood of diagnosing a Clinical Significant (≥ ISUP2) Prostate Cancer
    - PIRADS 5 ~60-70%
    - PIRADS 4 ~40-50%
    - PIRADS 3 ~ 15-20%

The Tower of Babel by Pieter Bruegel the Elder (1563)

MR-based mold

Patient-Specific MR-based Mold

Shah et al. *Rev Sci Instrum.* 2009 Oct; 80(10):104301 (Research Highlight for Oct '09 issue)

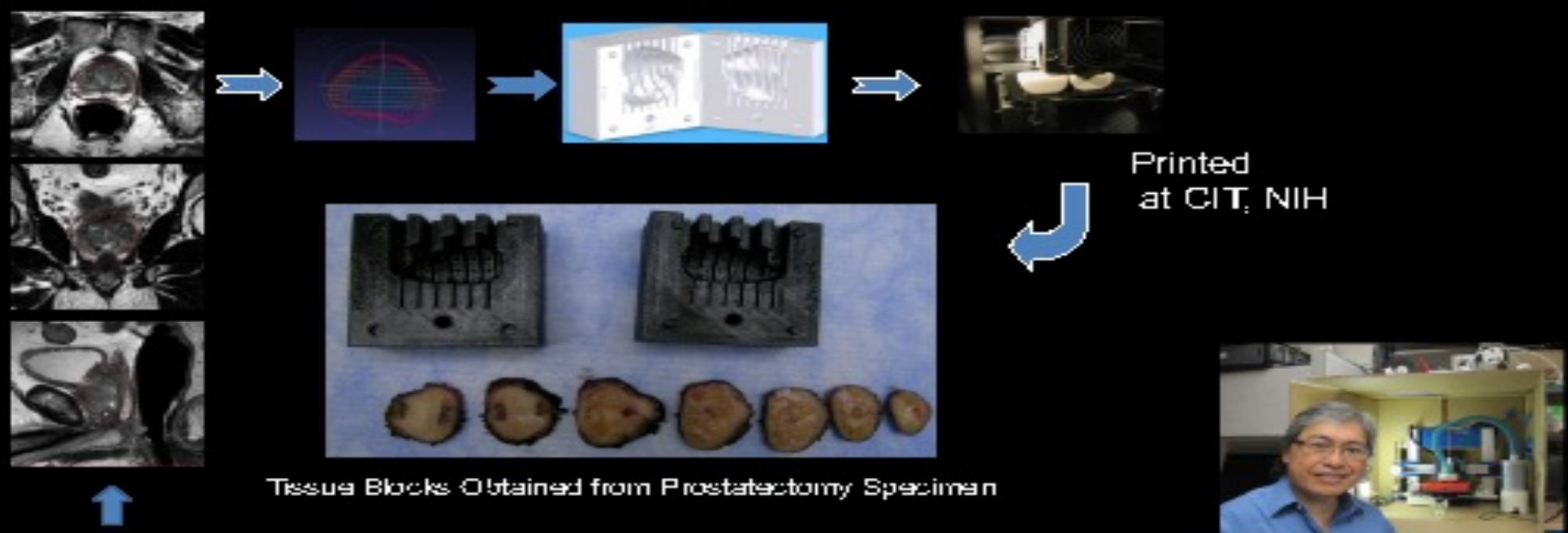

Marcelino Bernardo

Artificial intelligence sensitivity

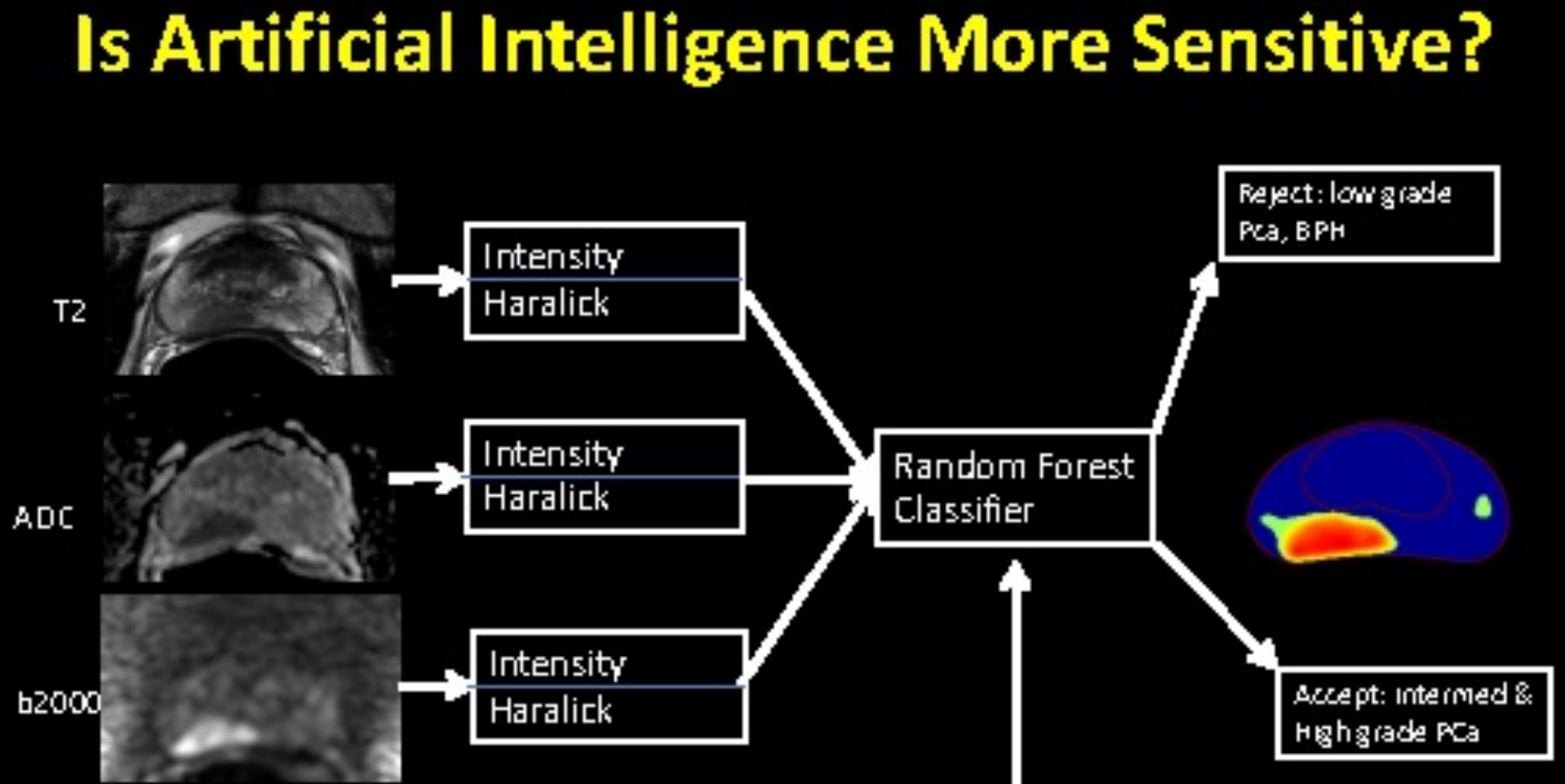

AI outperforms humans

AI Outperforms Trained Human Readers in Defining Lesion Contours

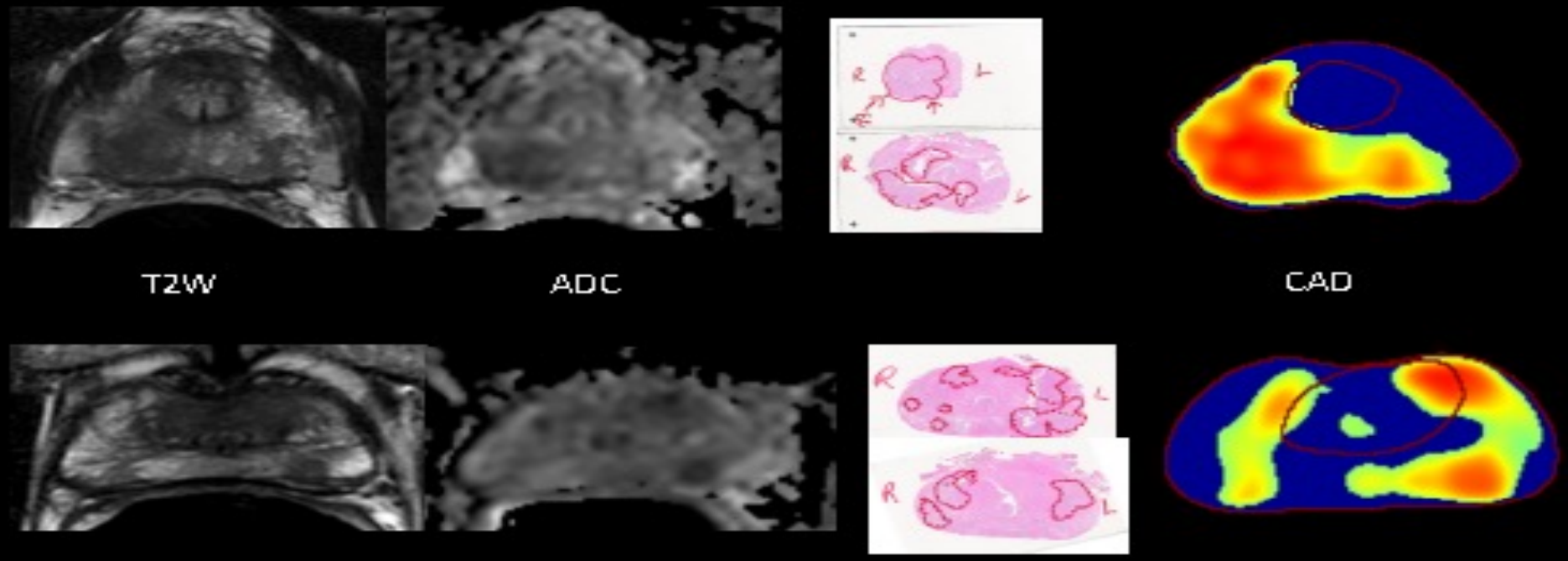

Lay N et al. SPIE proceedings 2016

MRI summary

Prostate MRI Summary

- MRI-US Fusion biopsy detects more clinically significant cancers and fewer insignificant cancers
- Level one evidence supports MR guided biopsy in lieu of sextant biopsies
- Concern over "missed" csPCa on MRI can be mitigated by
  - Continued observation
  - Consideration of clinical factors (PSA density)
  - Computer Aided Diagnosis (CAD)

Prostate cancer progression

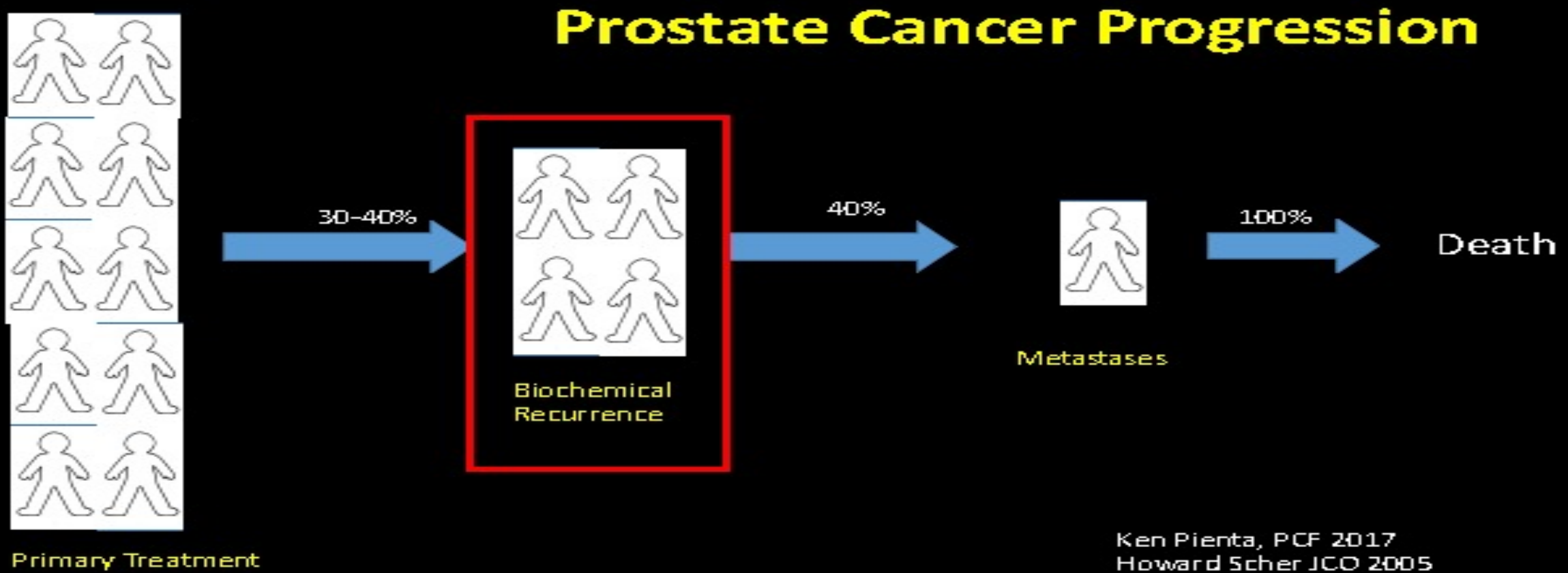

Prostate cancer history

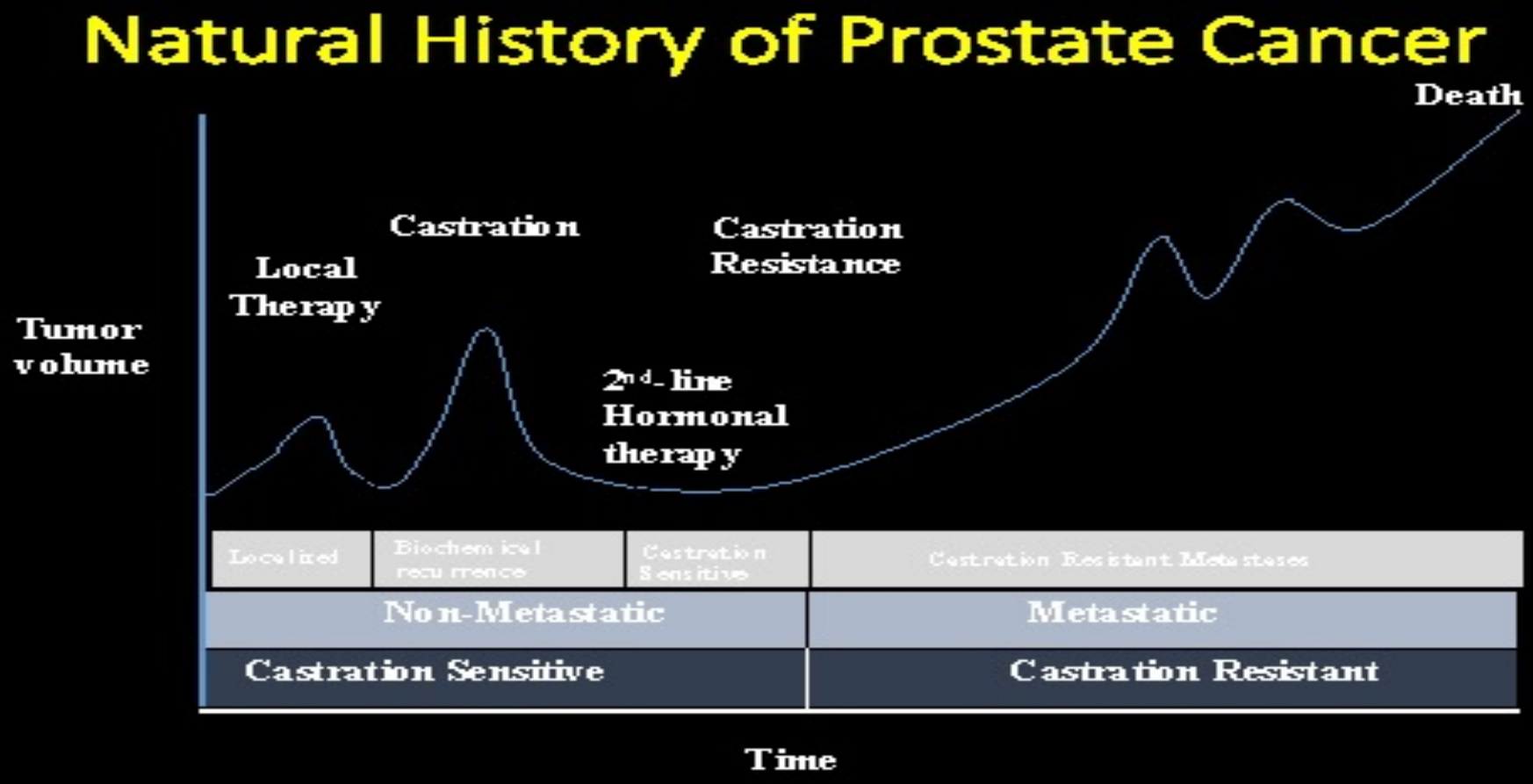

Ravi Madan, 2016

Case report

68 year-old man with a serum PSA of 0.5ng/dl after R/P for Gleason 4+4 disease

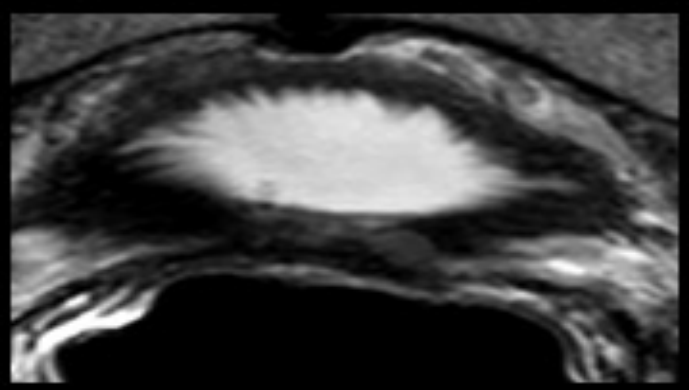

T2W MRI



DWI ADC map



Raw DCE MRI

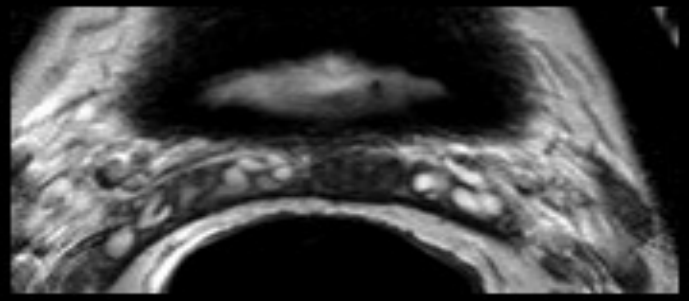

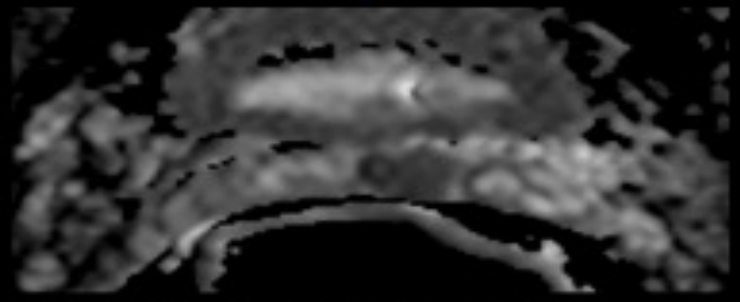

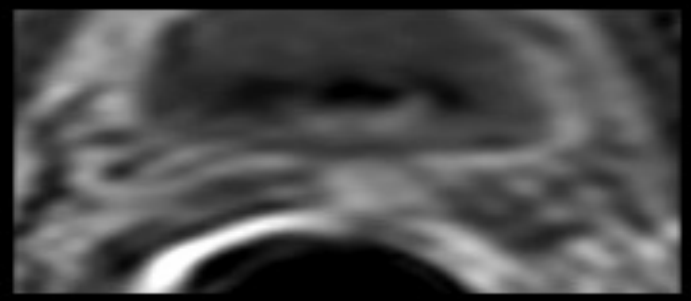

61 year-old man with a serum PSA of 5.4ng/dl after Brachytherapy for Gleason 4+3 disease disease

Brachytherapy

61 year old male, PSA=5.54ng/ml S/P brachytherapy 5 years ago



12 core systemic bx negative
Gleason 4+3 Pca in left SV

Traditional imaging

Traditional Imaging of Prostate Cancer

- Transrectal Ultrasound (TRUS) for guiding prostate biopsies
- Computed Tomography (staging)
- Tc-99m MDP Bone Scans
- Plain radiographs of the bone
- *New PET Scanning*

Computed tomography

Computed Tomography

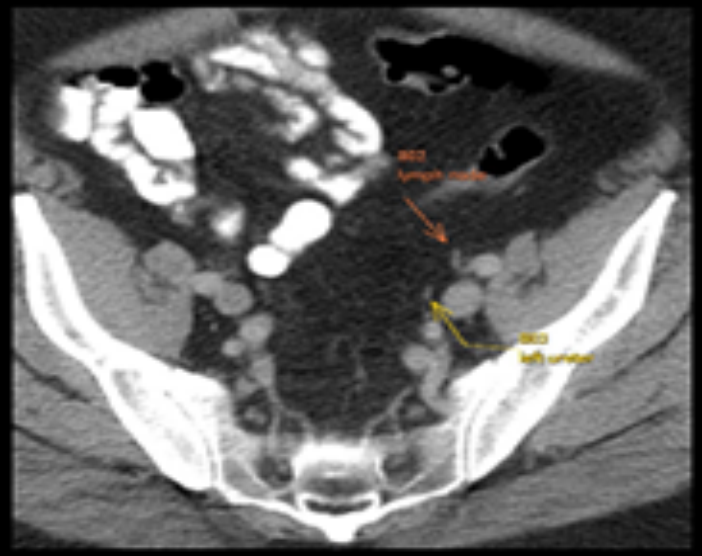

- For nodal staging, based on diameter/shape of the node
  - False negatives: small nodes harboring cancer
  - False positives: large inflammatory nodes
- For bone staging:
  - Osteoblastic lesions: benign or malignant?
  - Is disease live or dead?

Bone scan

Bone Scan

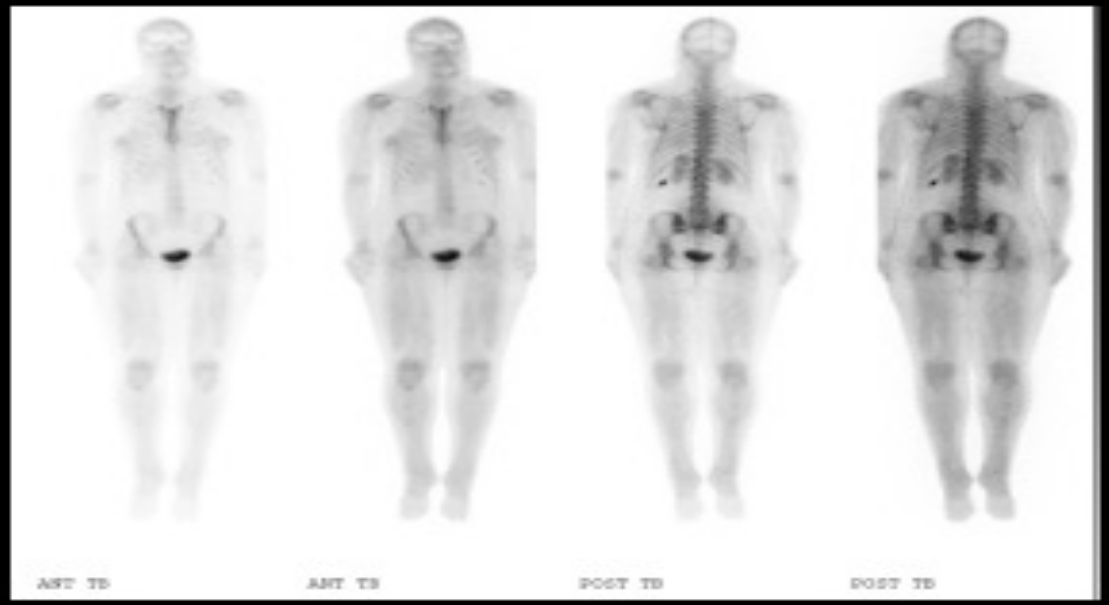

- Insensitive for small bone lesions
- Non specific (benign lesions)
- Difficult to localize lesions
- Takes 3-5 hours

^{18}F

Very high sensitivity (pM-nM)
Quantitative
± Spatial resolution 3-4mm

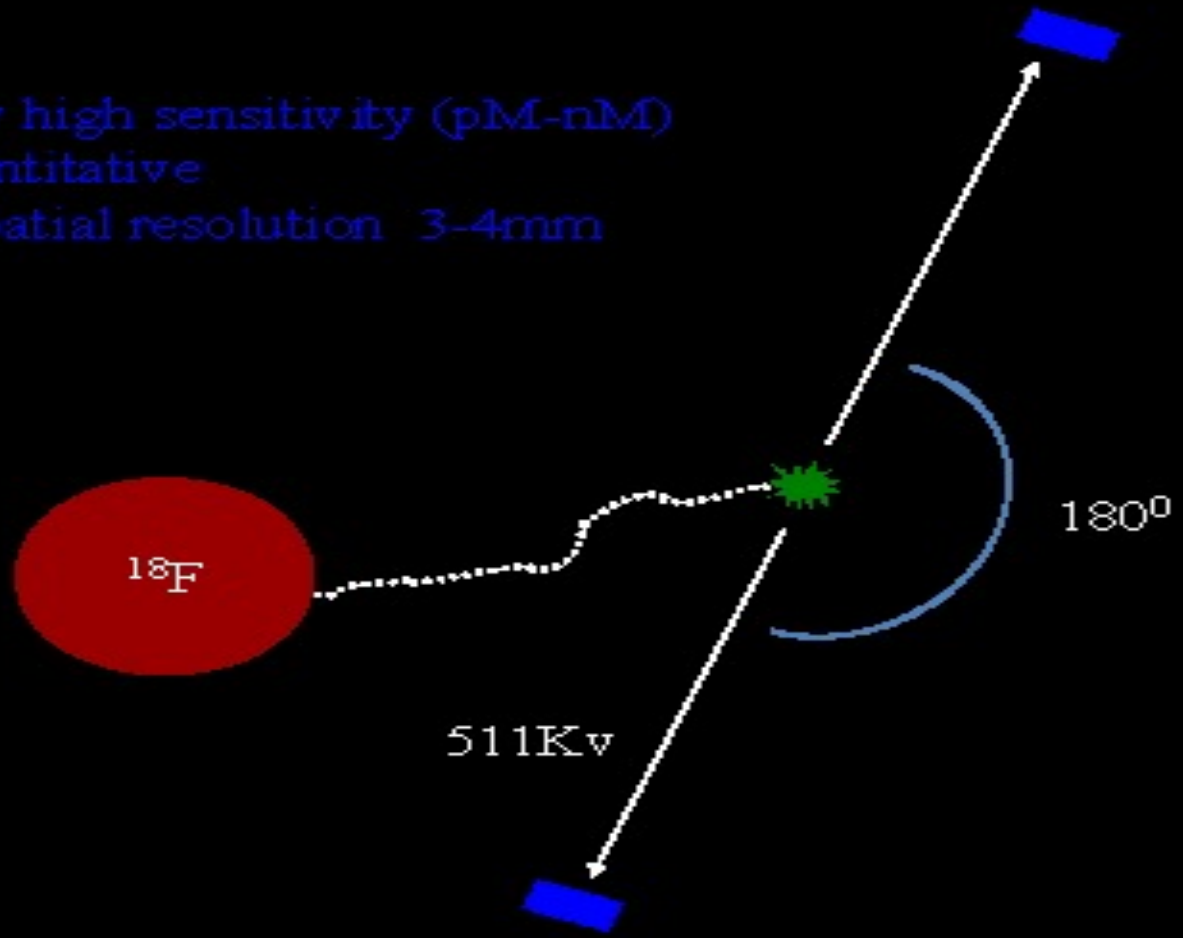

PET/CT camera

PET/CT Camera

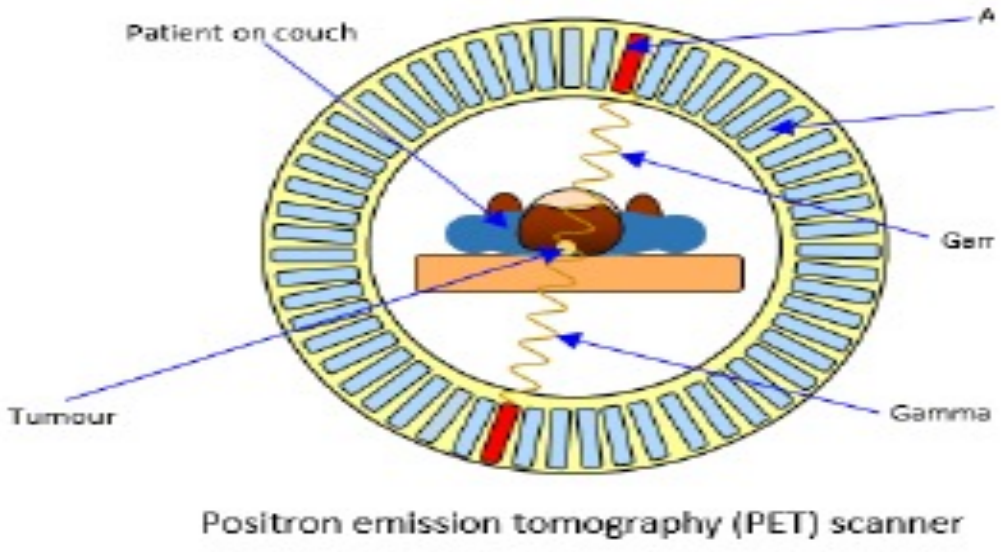

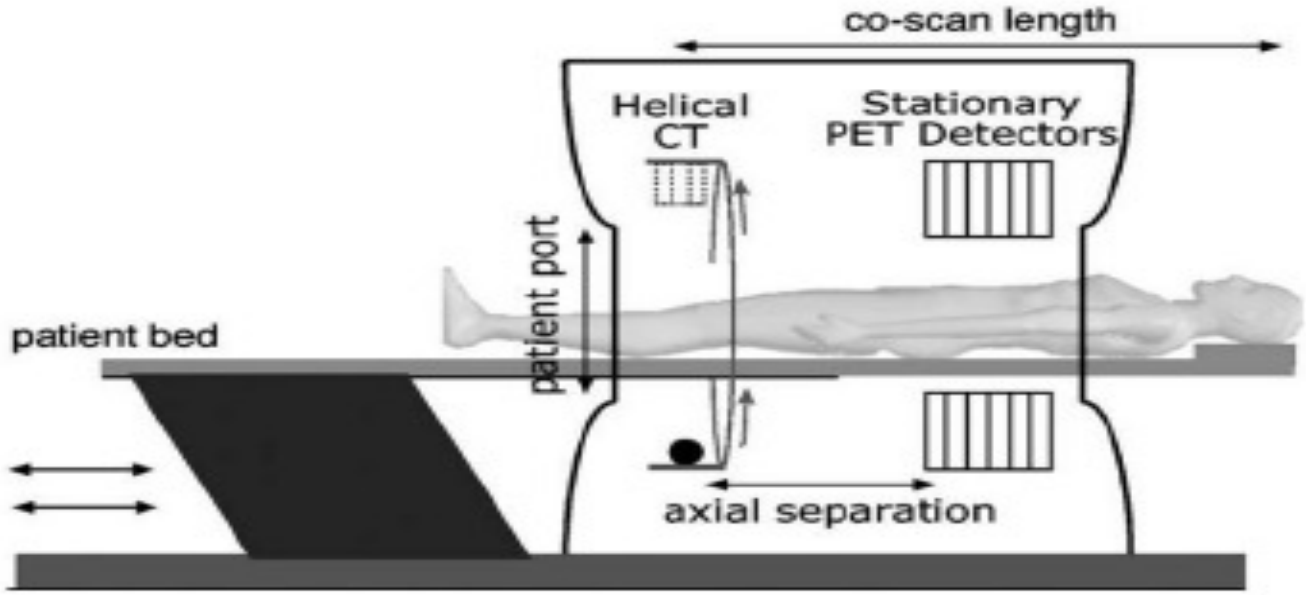

PET-CT scanners

PET-CT scanners

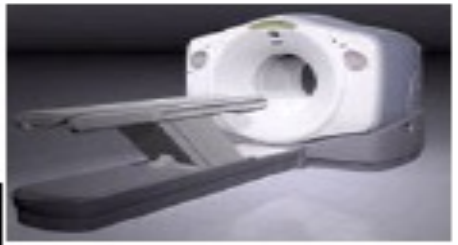

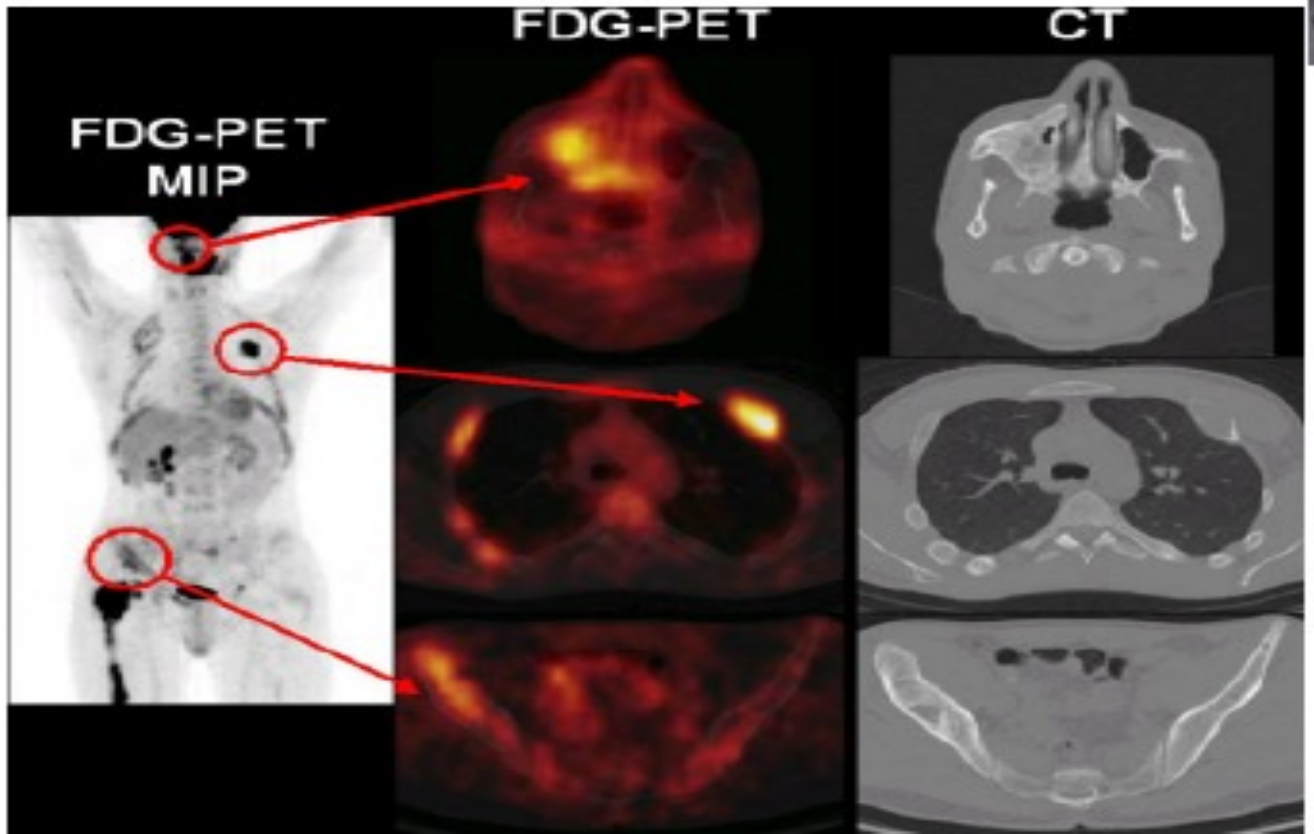

Prostate specific membrane antigen

Prostate Specific Membrane Antigen (PSMA)

•PSMA (prostate specific membrane antigen) is a transmembrane protein, which is highly expressed in many prostate cancers, particularly high grade cancers.

• Urea-based compounds have high affinity for the enzymatic domain of PSMA and are used for PET imaging

Marty Pomper MD PhD

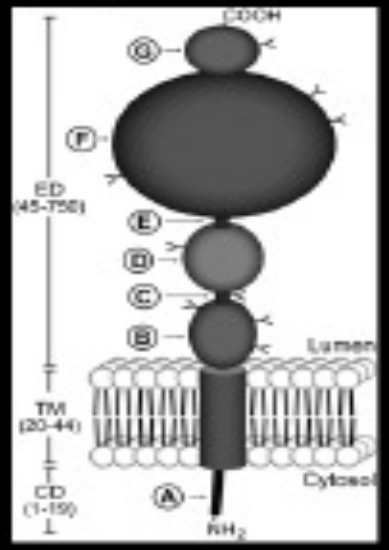

PSMA receptor

http://alpha.fi.physiol.bgy.org/content/2009/3/C773

NeXT project ligands

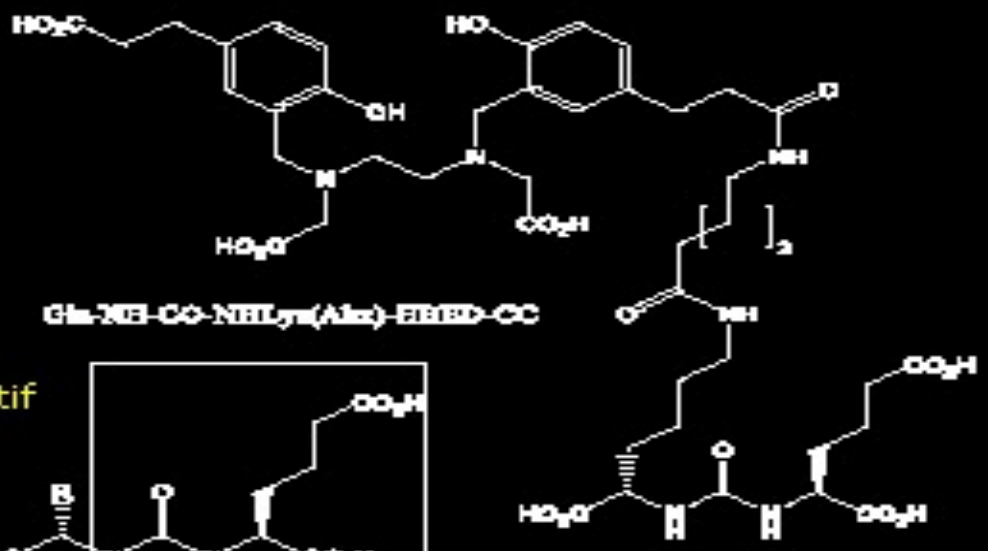

Glu-NH-CO-NHLys(Ahx)-HBED-CC

Urea binding motif

In square, common to all structures

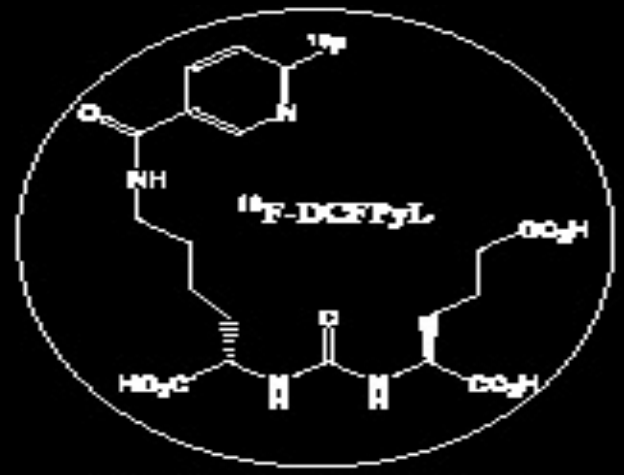

Second NIH Agent 2017
Commercialization underway

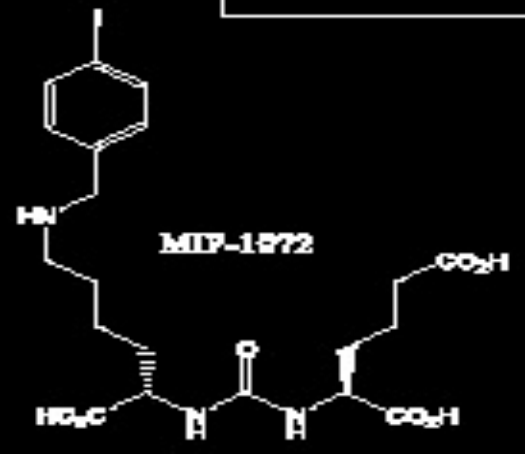

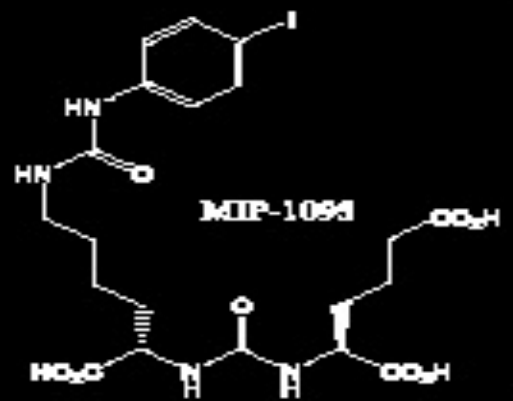

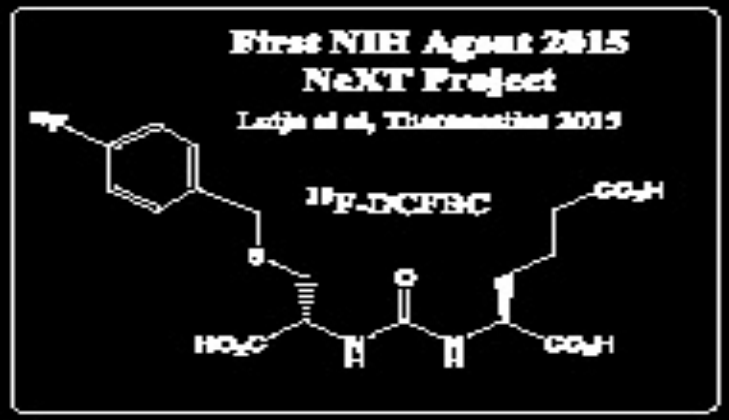

Local recurrence

Local Recurrence: DCFPyl PET/CT

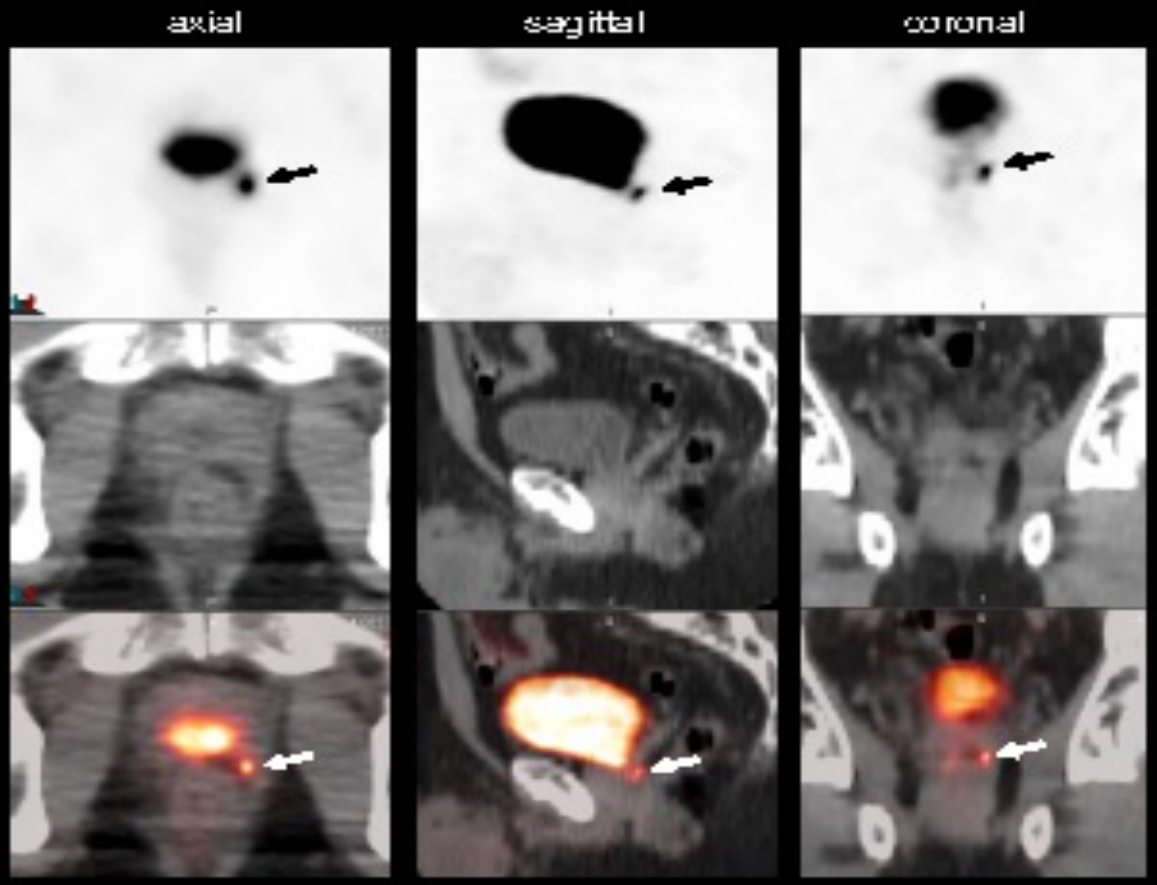

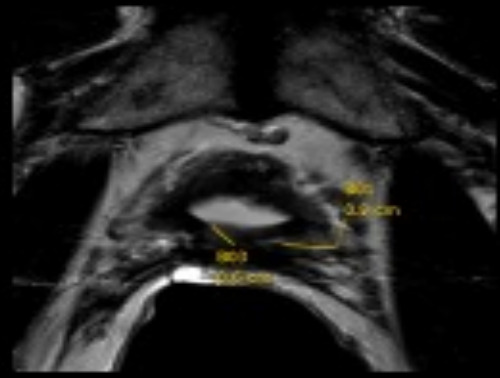



Lua Lindenberg

Esther Mena

Status post-prostatectomy (2007) Recent PSA (10/02/17) = 1.29 ng/mL.

Local recurrence

Local Recurrence DCFPyl PET/CT

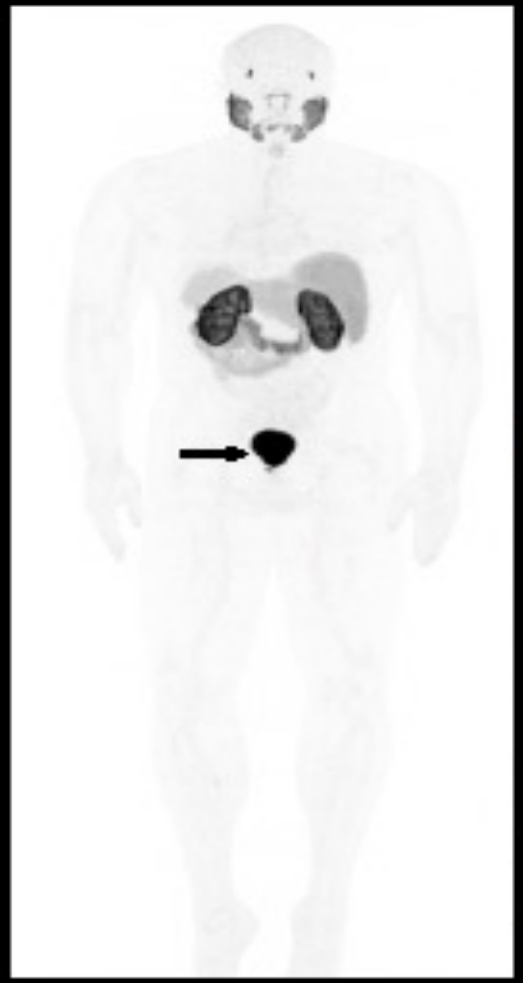

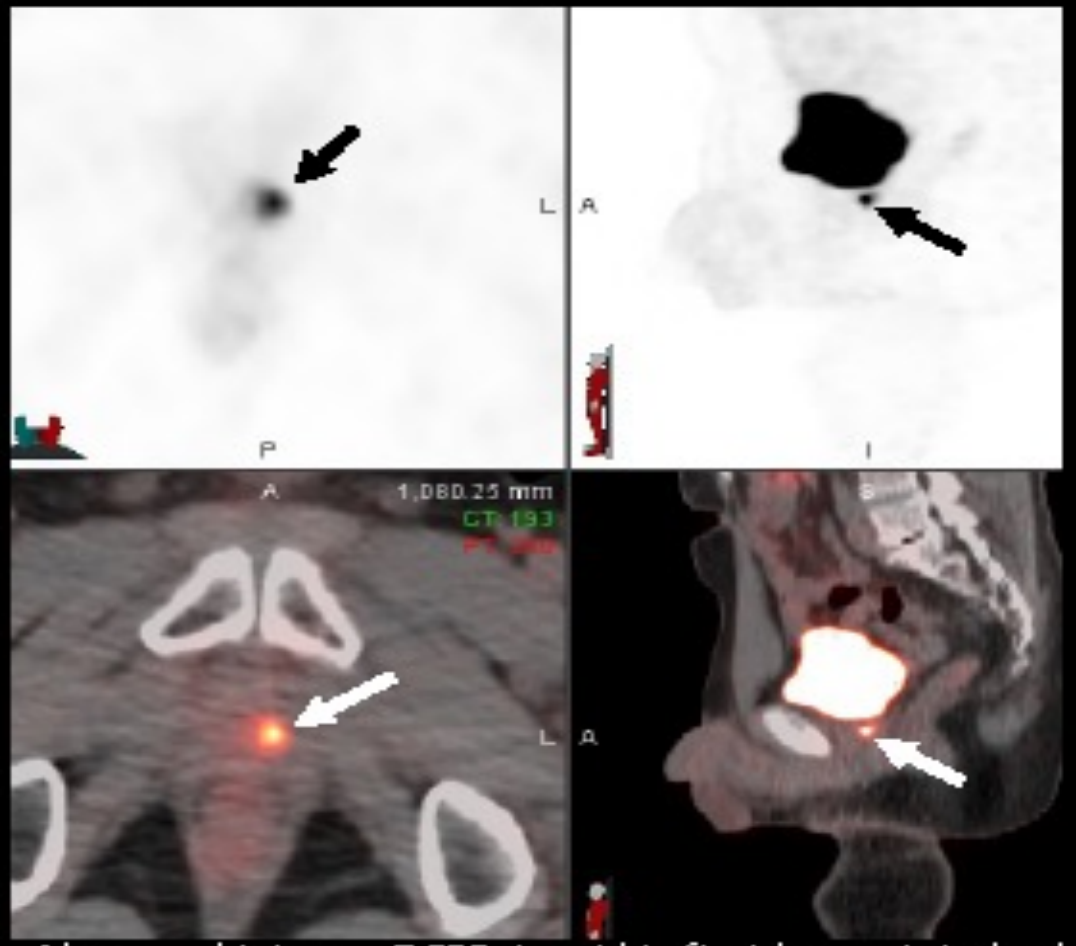

Abnormal intense DCFPyL-avid Left-side prostate bed

Protocol 17-C-0109_BCR; DCFPyL #006 s/p Prostatectomy in 2013 (multifocal carcinoma, Gleason score 3+3, negative margins (staged pT2c pNx). Salvage radiation therapy 70.2 Gy from 03 to 05 2014. Post-radiation PSA nadir was 0.040 in 5/2015. Rising with PSA, now 3.09 ng/mL on 09/22/2017

Deb Citrin

Lymph node metatases

Lymph Node Metastases

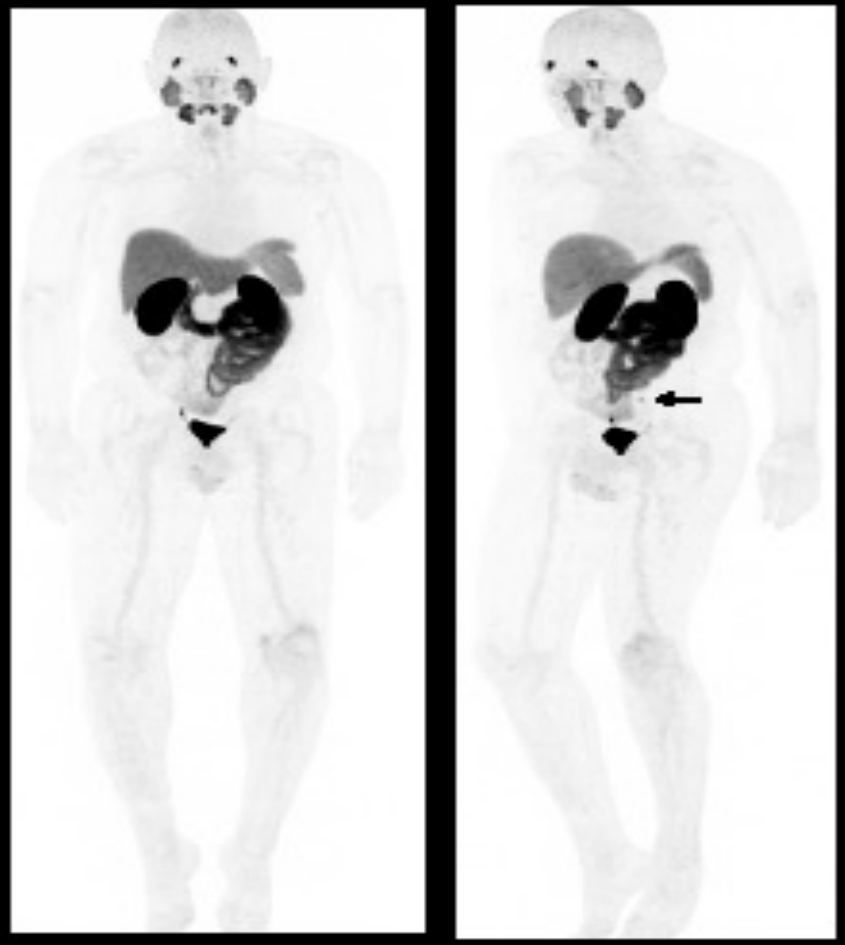

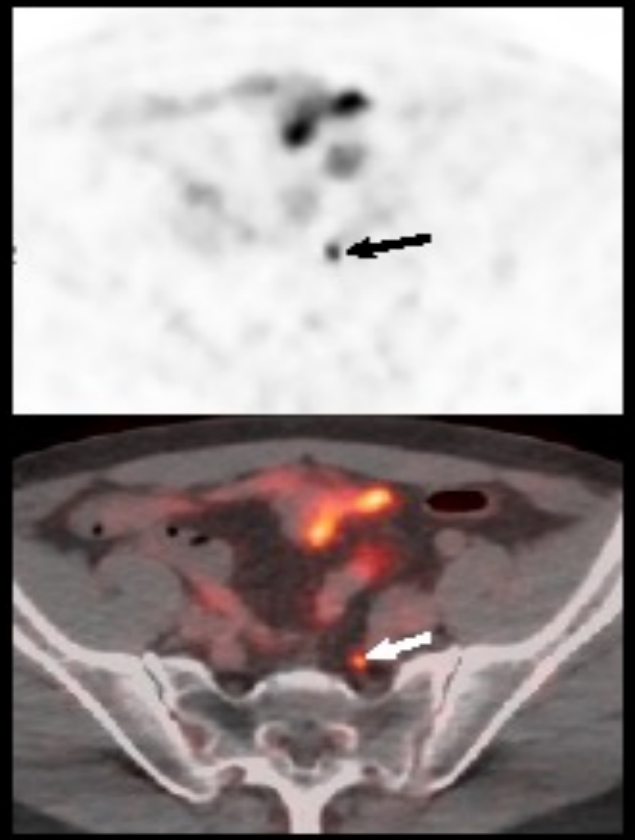

Status post-radical prostatectomy (03/2017), pT3a pN0 MX, Gleason 4 + 3 with tertiary pattern 5 with extraprostatic extension. PSA (11/29/2017)= 0.40 ng/mL

Lymph node recurrence

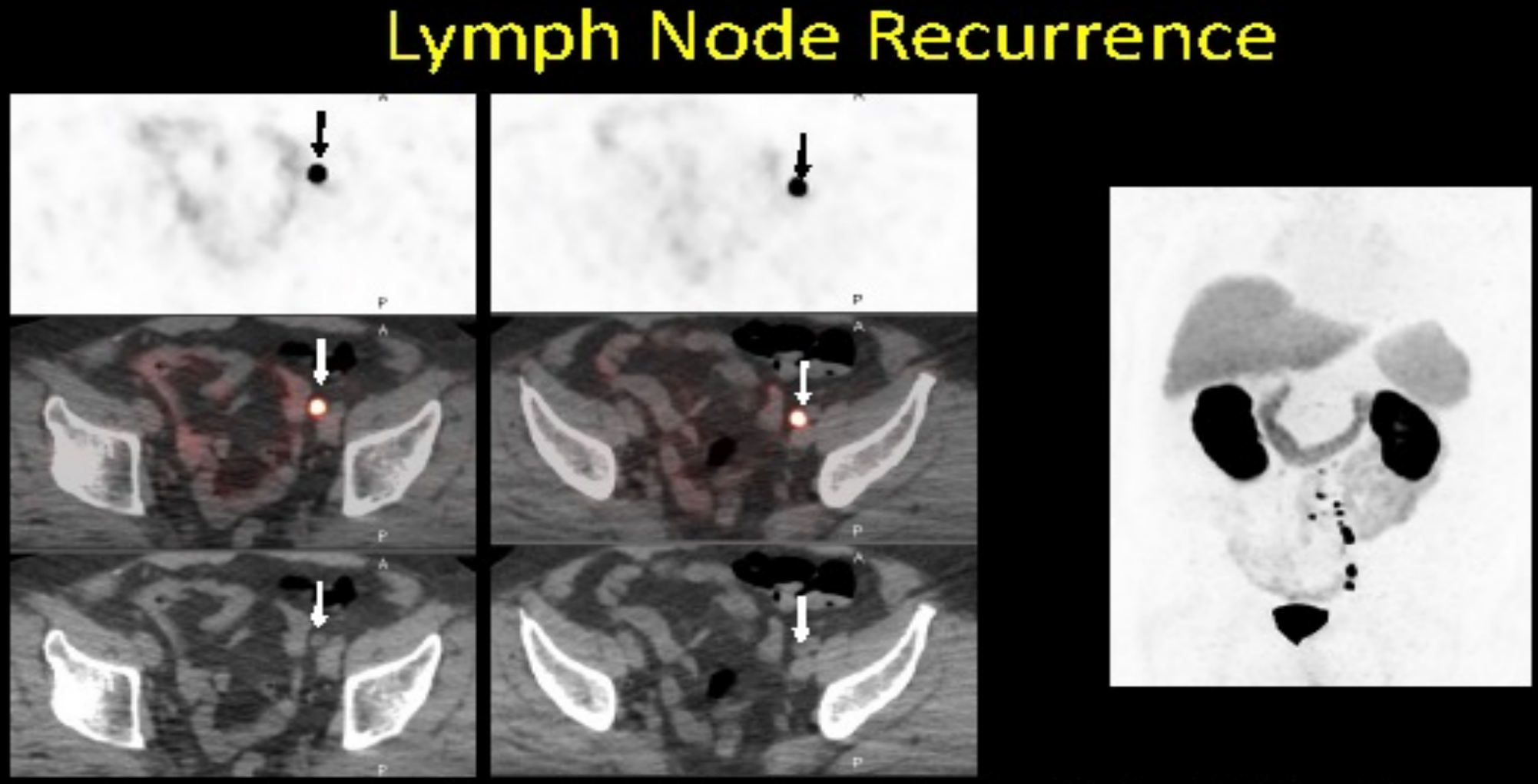

72 year old male with prostate adenoCa, s/p prostatectomy (2003) stage IIb:
pT2cN0 Gleason 7 (4+3) PSA (01/09/2018)= 7.42 ng/mL.

Lymph node and bond metastases

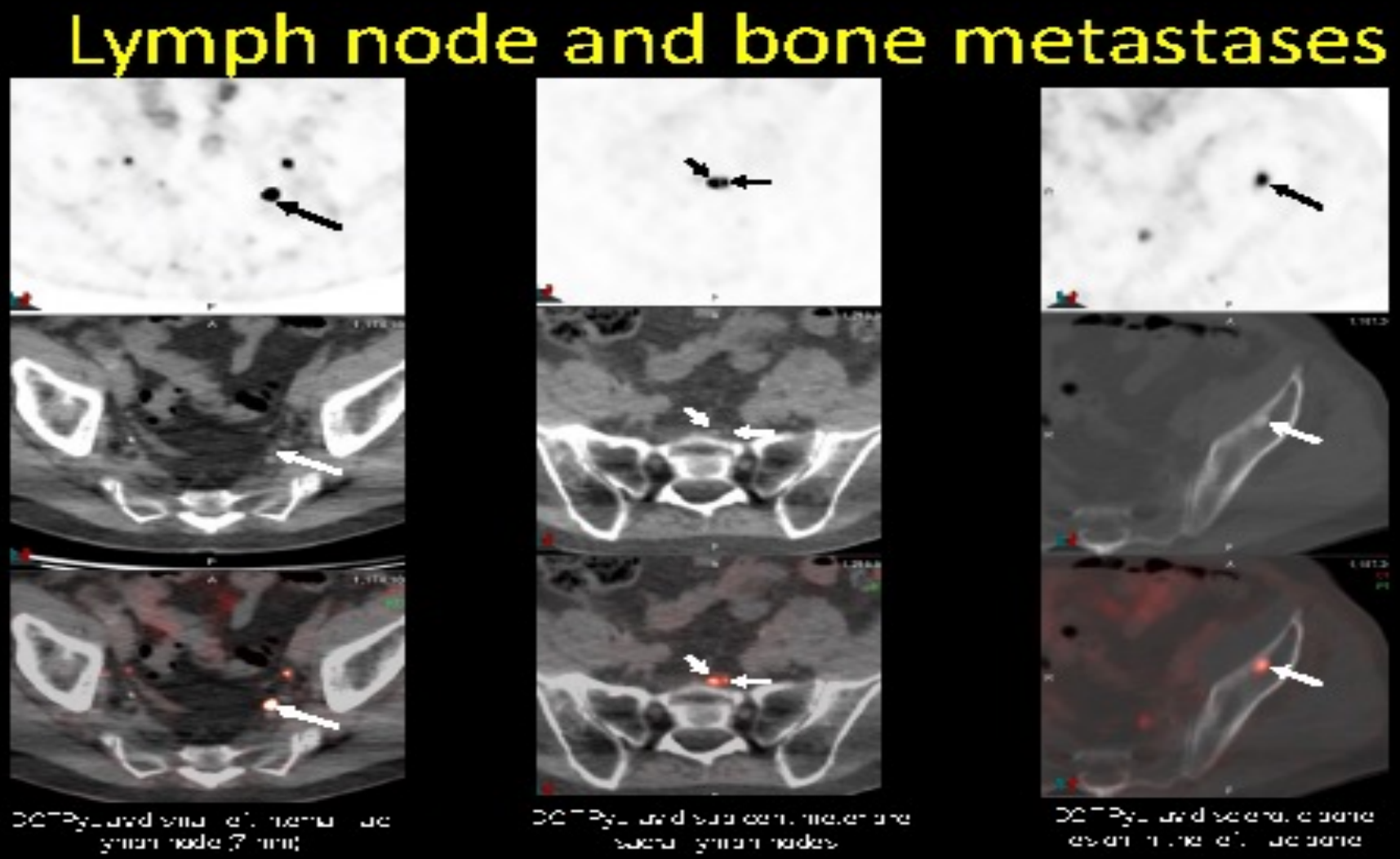

s/p prostatectomy 08/2010, Gleason 4+3=7 with SV extension, negative margins.
PSA (11/29/2017)= 13.29 ng/mL

Case report

17C-0089 - DFBPyL # 0011 (RG) 08/17/2017- PSA= 5.61 ng/mL

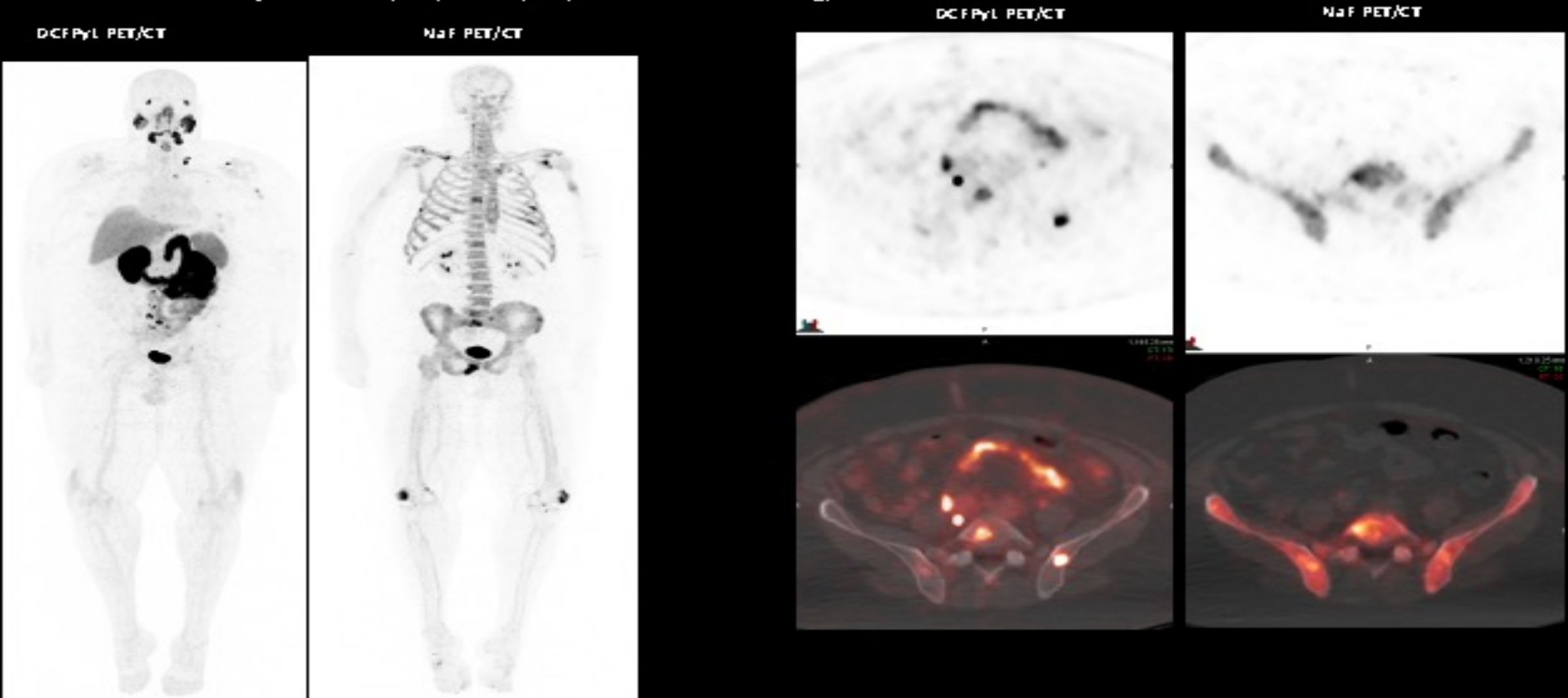

Case report

Protocol 17C-0089
DCFPyL #00xx
Small cell variant

DCFPyL PET imaging

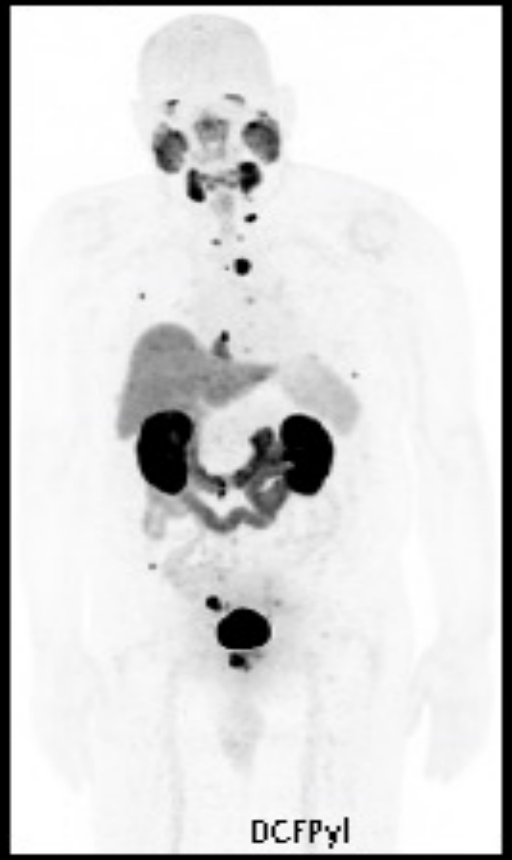

FDG PET imaging

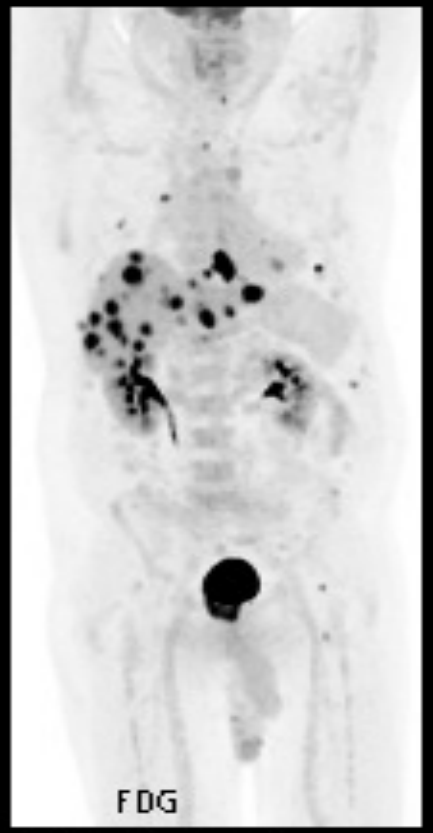

No significant abnormal DCFPyL uptake within the multiple FDG-avid liver lesions or within the FDG-avid bilateral pulmonary nodules

Case report

Protocol 17-C-089
DCFPyL #060 _FU
7988063

Response to ADT

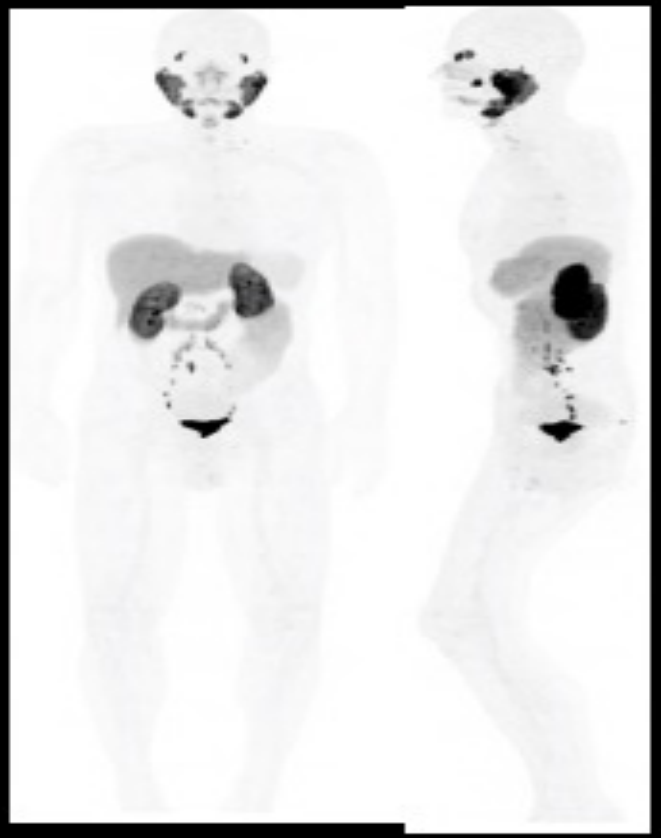

^{18}F-DCFPyL PET/CT imaging

01/03/20

PSA = 13.59 ng/mL

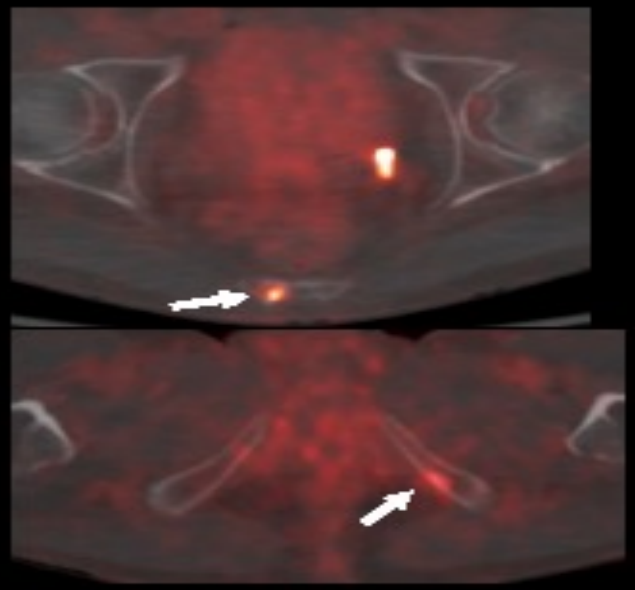

DCFPyL-avid sclerotic bone lesions at the R lower sacrum and Left ischium

^{18}F-DCFPyL PET/CT imagi

10/05/20

PSA: 0.04 ng/mL

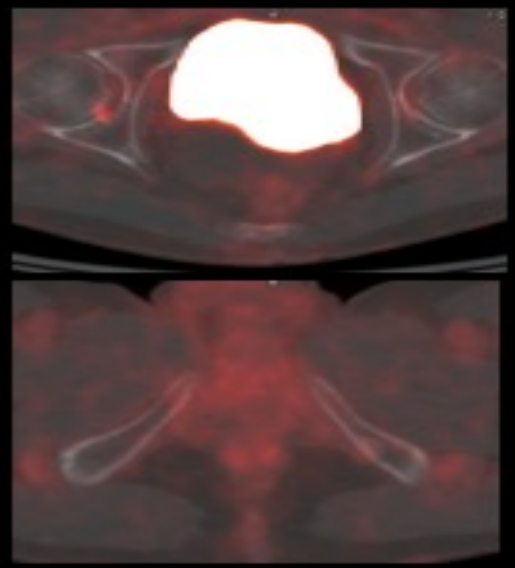

Interval complete resolution of the DCFPyL uptake at the bone sclerotic lesions (R lower sacrum and L ischium)- sclerosis persists but the PSMA-PET uptake has resolved

Radionuclides

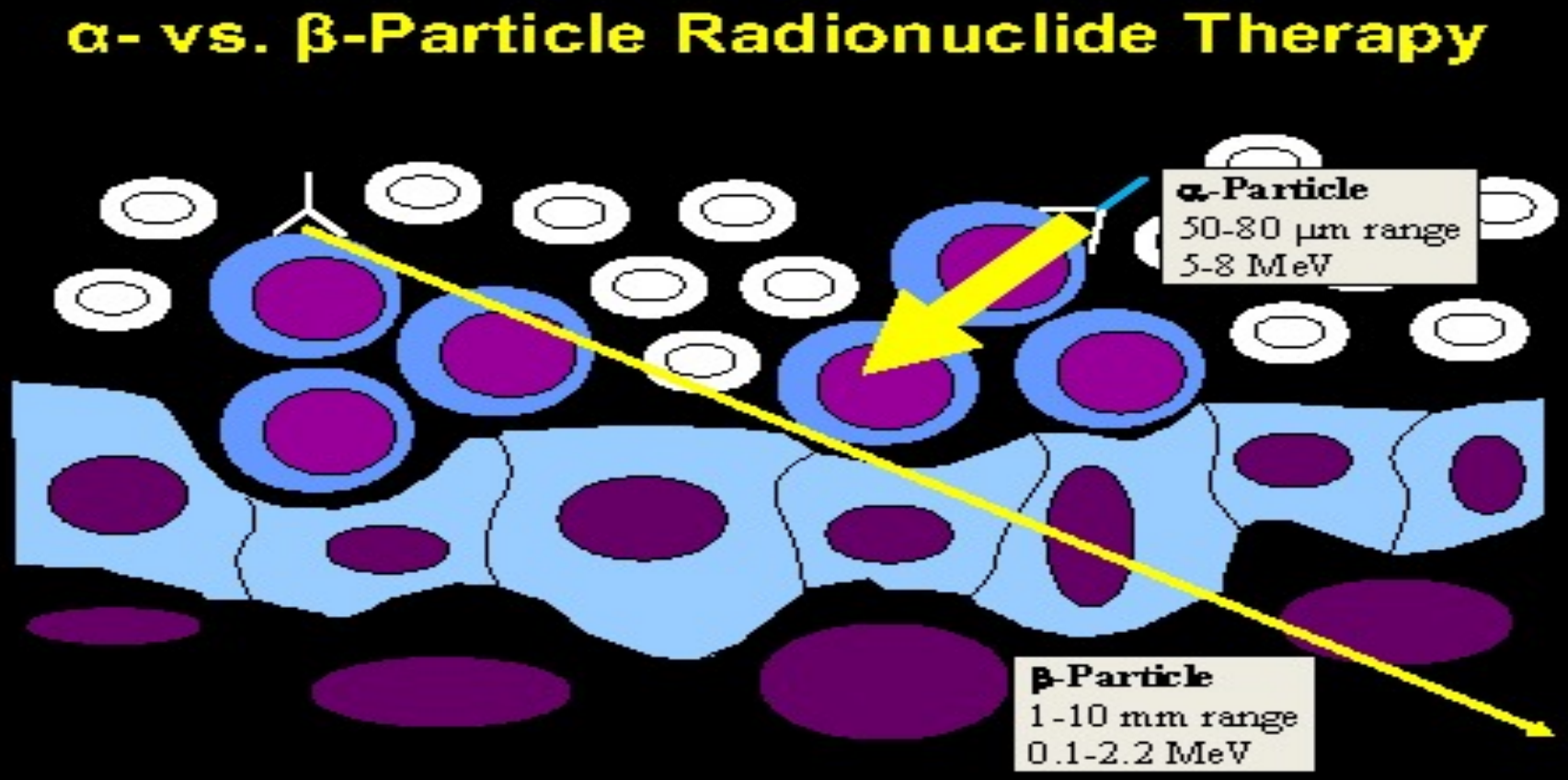

Milenic, Brady, and Brechbiel Nature Rev Drug Disc 2004

Case report

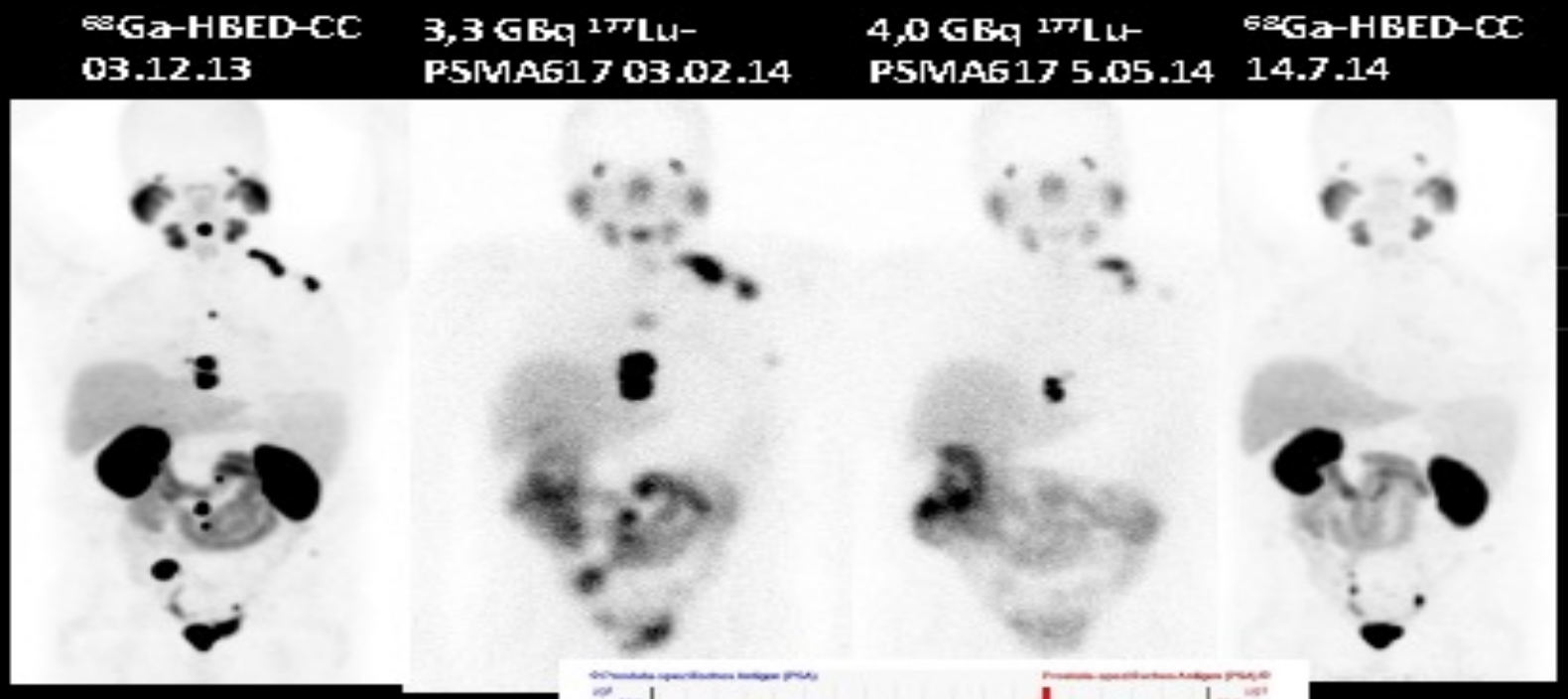

Freddie Giesel

Frank Lin

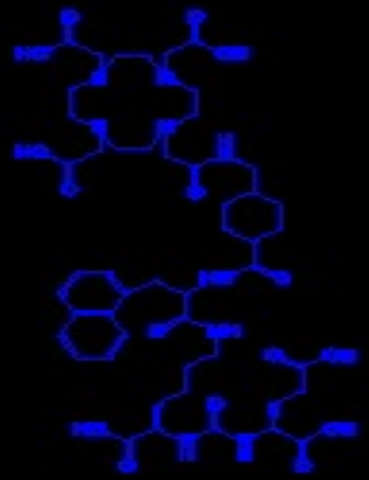
^{177}Lu-PSMA617

dkfz.

Case report

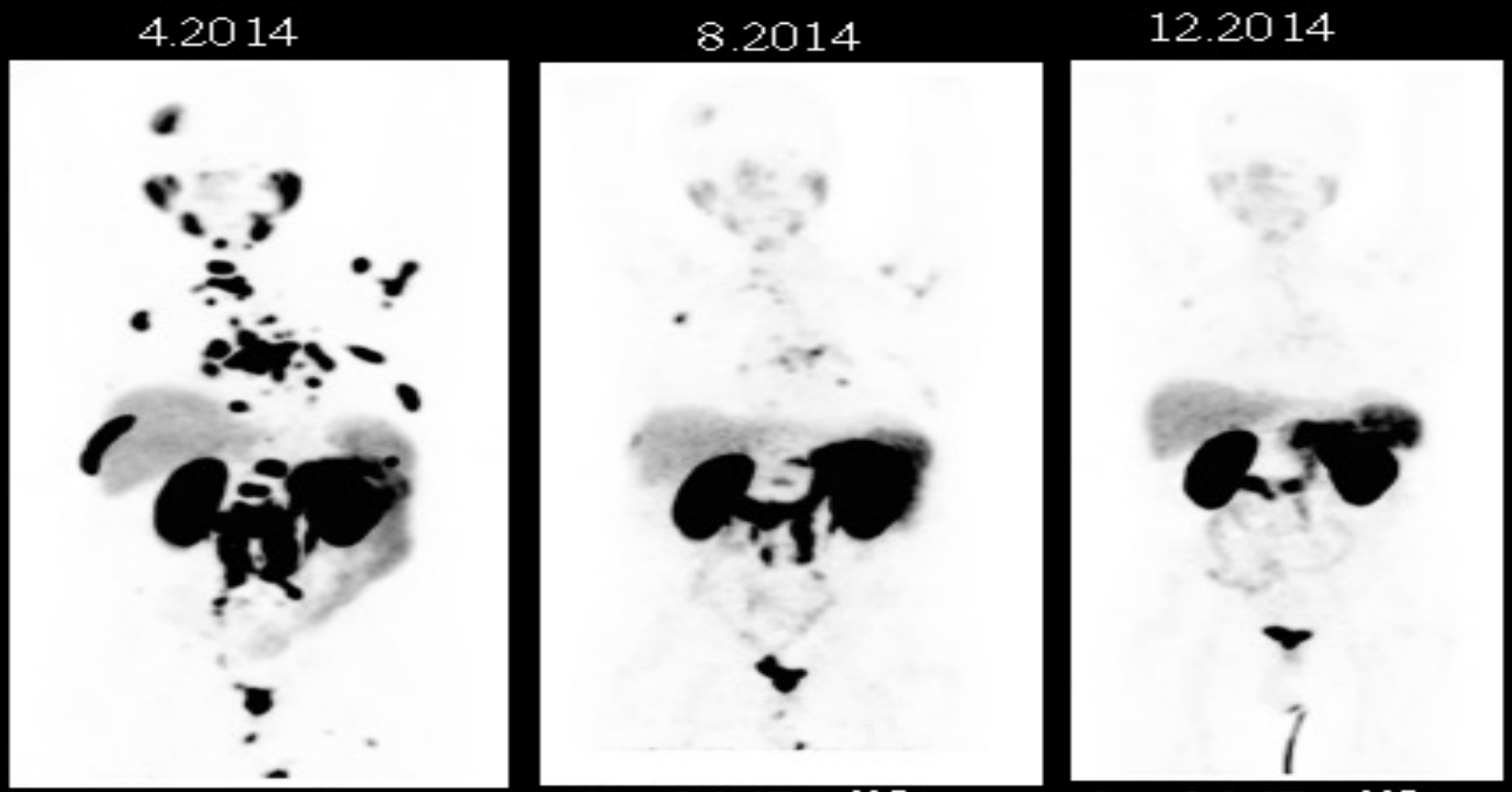

dkfz.

SUMMARY

PSMA PET/CT Summary

- PSMA PET imaging is a breakthrough technology for detecting recurrent and metastatic prostate cancer
  - Earlier and more precise therapy for recurrent disease
  - Better chance of cure
- PSMA can also be used for Targeted Radionuclide Therapy to kill cancers harboring PSMA+ cells
  - Efforts are ongoing to maximize treatment while minimizing side effects
  - PSMA "Window" may limit true extent of disease extent

SUMMARY

Overall Summary

- Diagnosis of prostate cancer is aided by use of MRI that can localize tumors for image guided biopsy (vs. random biopsy)
- MRI can be used to follow patients on active surveillance
- Once a patient undergoes therapy they can recur:
  - PSMA PET/CT is most sensitive modality for detecting recurrence
  - Disease can progress to metastatic disease
  - PSMA PET can be used to monitor patients although CT and bone scan are still the standard of care

Acknowledgments

MIP
Baris Turkbey
Liza Lindenberg
Yolanda McKinney
Esther Mena
Steve Adler
Dagane Daar
Thieu Hoa
Philip Eclarinal
Alicia Forest
Juanita Weaver
Stephanie Harmon
Sherif Mehralivand
Marcin Czarniecki
Mirna Martinez
Sonia Gaur
Clayton Smith
Matthew Greer
Karen Wong
Gary Griffiths
Frank Lin
Froddy Escorcia
Elaine Jagoda
Hisataka Kobayashi

Urology
Peter A. Pinto
Interventional Radiology
Brad Wood
Eliot Levy
Richard Chang
Venkatesh Krishnasamy (Kavi)
Sheng Xu
Radiation Oncology
Deborah Citrin
Lindsay Rowe
Medical Oncology
Ravi Madan
William Dahut
David VanderWeele
James Gulley
Anna Couvillon
Pathology
Maria Merino
Lab of GU Cancer Pathogenesis
Kathleen Kelly
Adam Sowalsky
JHU
Martin Pomper
Steve Rowe

CC Radiology
Elizabeth Jones
Ronald Summers
Les Folio
Ashkan Malayeri
Nathan Lay
CIT
Raisa Freidlin
Thomas Pohida
Biometrics Branch
Joanna Shih
Radiation Biology
Murali Cherukuri
Kazu Yamamoto
Jeff Brender
PET Department
Michael Channing
Peter Herscovitch
Image Probe Development Center
Rolf Swenson
Falguni Bhattacharyya
Ana Opina
Olga Vasalatiy
Haibo Wu
Tech Transfer
Tom Clouse